

# Acetabular Labral Tear and Postpartum Hip Pain

Adam G. Brooks, MD, and Benjamin G. Domb, MD

**OBJECTIVE:** To educate the obstetrics community regarding postpartum labral tears, an avoidable and treatable potential complication of pregnancy in the postpartum period.

**METHODS:** From 2009 to 2011, 10 women presented to the second author's office with persistent hip pain that had begun during pregnancy or during delivery. These 10 postpartum women presented with signs and symptoms of labral tears, which were subsequently confirmed with arthroscopy and surgically repaired.

**RESULTS:** Each patient experienced relief of symptoms within 4 months after the procedure. All patients were satisfied with surgery, and all patients had improvement in modified Harris hip score. The average preoperative modified Harris hip score was 53.1 and the average postoperative modified Harris hip score was 84.3 ( $P < .001$ ).

**CONCLUSION:** An acetabular labral tear should be considered part of the differential diagnosis for hip pain in postpartum women. Additionally, freeing the distal lower extremity to externally rotate during labor may prevent an acute labral tear. When non-operative management fails, surgery may lead to positive outcomes.

(*Obstet Gynecol* 2012;120:1093–98)

DOI: <http://10.1097/AOG.0b013e31826fbcc8>

LEVEL OF EVIDENCE: II

---

From the San Francisco Orthopaedic Residency Program, St. Mary's Medical Center, San Francisco, California; the American Hip Institute; and Loyola University Stritch School of Medicine, Hinsdale Orthopaedic Associates, Chicago, Illinois.

Supported by funding for the illustrations was provided by The Taylor Collaboration, St Mary's Medical Center, San Francisco, California, which is associated with the San Francisco Orthopaedic Residency Program.

The authors thank Kate Daly, Medical Illustrator, for completing the illustrations.

Corresponding author: Adam G. Brooks, MD, 450 Stanyan Street, San Francisco, CA 94117; e-mail: [adam.guy@gmail.com](mailto:adam.guy@gmail.com).

---

#### Financial Disclosure

The authors did not report any potential conflicts of interest.

---

© 2012 by The American College of Obstetricians and Gynecologists. Published by Lippincott Williams & Wilkins.

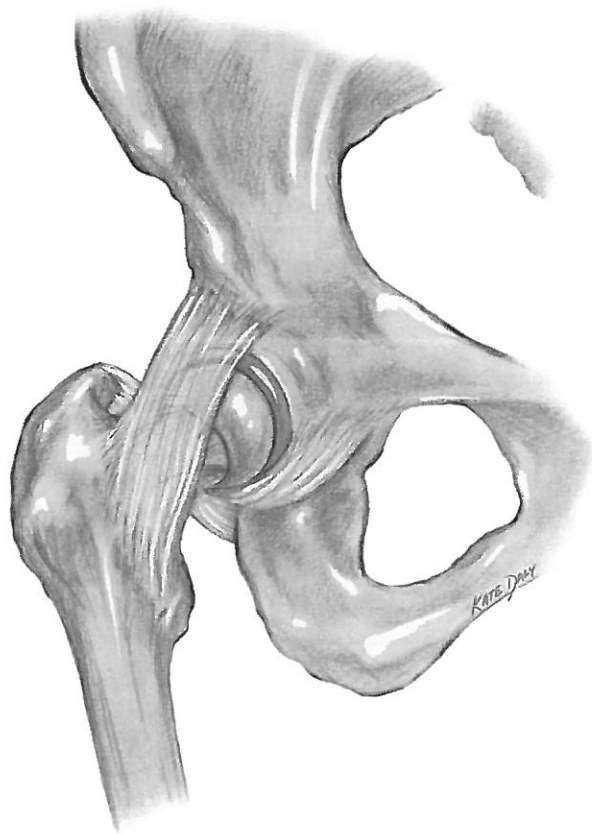ISSN: 0029-7844/12

Hip pain in the postpartum woman can be a difficult problem to diagnose and subsequently treat without a high index of suspicion for a variety of orthopedic conditions. Pathology affecting the lower back, pelvis, or hip can occur, and health care providers must be aware of a range of problems for proper diagnosis and treatment. Although orthopedic problems such as pregnancy-related posterior pelvic pain, lumbar disc herniation, cauda equina syndrome, mechanical lower back pain, pubic symphysis rupture, and pelvic girdle pain have been previously described in the literature,<sup>1–6</sup> to our knowledge, only one previous article has mentioned acetabular labral tears as a source of hip pain specifically in the postpartum woman, which was a series of three women.<sup>7</sup>

Labral pathology has gained much recent attention as a cause of nonarthritic hip pain in the young adult. The acetabular labrum is a ring of fibrocartilage extending from the edge of the acetabulum that deepens the hip socket (Fig. 1). The labrum serves several important biomechanical functions in the hip including regulation of synovial fluid, protection of the articular cartilage, providing a suction seal for hip stability, and load-bearing at the hip.<sup>8</sup> A damaged labrum is unable to perform some or all of these jobs depending on the extent of the pathology.

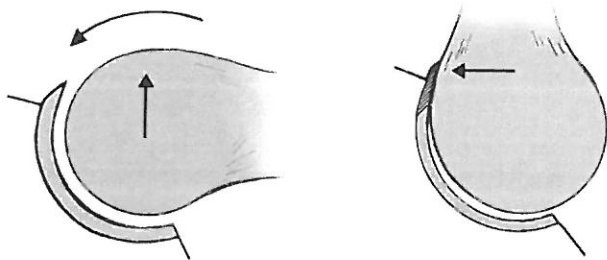
Labral damage can be caused by underlying femoroacetabular impingement with or without an acute traumatic event. Two types of lesions cause femoroacetabular impingement: cam lesions of the femoral head and pincer lesions of the acetabular rim (Figs. 2, 3, and 4). Cam lesions occur when an abnormal, nonspherical femoral head jams into the acetabulum during normal motion. The oblong femoral neck causes avulsion of the labrum from the rim and acetabular chondral damage in the anterosuperior region. Pincer lesions occur when the acetabular rim overcovers the femoral head. The initial damage in pincer lesions is the anterosuperior labral region, but subsequent contra-coup injury can result in the posteroinferior region.<sup>8</sup>





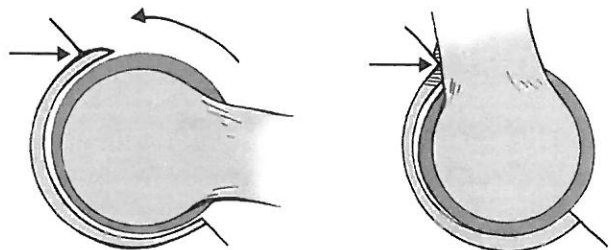
**Fig. 1.** Illustration of the hip. Illustration by Kate Daley. *Brooks. Postpartum Labral Tears. Obstet Gynecol 2012.*

We present a case series of 10 postpartum women with clinically and radiographically diagnosed acetabular labral pathology confirmed by hip arthroscopy. Our goal is to inform the clinician of labral pathology and femoroacetabular impingement as a possible



**Fig. 2.** Cam lesion of the femoral head. The asphericity of the femoral head is such that when the hip flexes, the anterior labrum is impinged between the acetabulum and the oblong femoral head. The arrow on the left image points to the irregularity of the femoral head, and the arrow on the right image points to the site of impingement. Illustration by Kate Daley.

*Brooks. Postpartum Labral Tears. Obstet Gynecol 2012.*



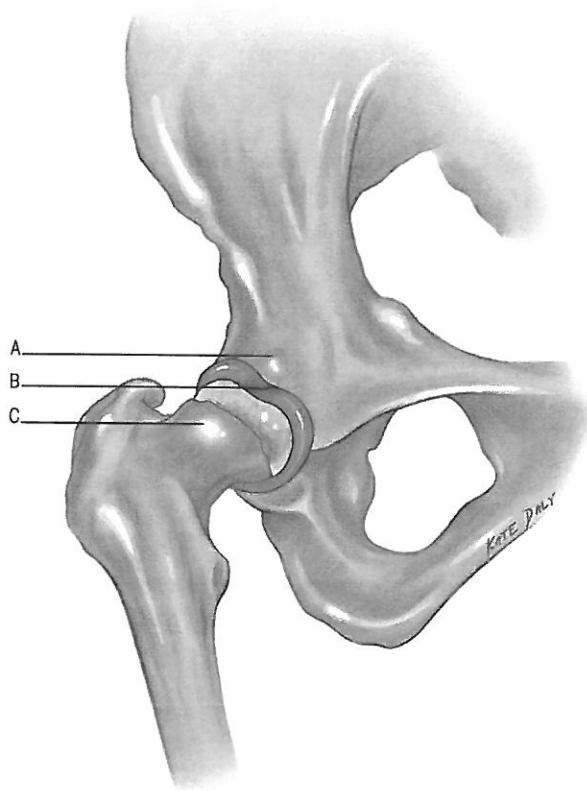
**Fig. 3.** Pincer lesion of the acetabulum. The overcoverage of the acetabulum is such that when the hip flexes, the labrum is impinged between the overhanging acetabulum and the femoral head. The arrow on the left image points to the irregularity of the acetabulum, and the arrow on the right image points to the site of impingement. Illustration by Kate Daley.

*Brooks. Postpartum Labral Tears. Obstet Gynecol 2012.*

cause of postpartum hip pain and to propose simple guidelines that may help reduce the incidence of labral tears during delivery.

### MATERIALS AND METHODS

From 2009 to 2011, 10 women presented to the second author's office with persistent hip pain that had



**Fig. 4.** Illustration of a labral tear (B) with sites of cam (C) and pincer (A) lesions. Illustration by Kate Daley.

*Brooks. Postpartum Labral Tears. Obstet Gynecol 2012.*



started during pregnancy or during delivery. These women ranged in age from 23 to 36 years. All women were managed by different obstetricians, but all were subsequently managed at the same subspecialized orthopedic center for the labral pathology. None of the women had previous hip symptoms. Two of the 10 women were recreational runners, and no other activity was common to all of the women. Four of the 10 women recalled a specific injury that occurred during the actual delivery, including a pop, twist, or sudden sharp pain in the hip. In all cases of acute onset during delivery, the mechanism of injury was forceful flexion and internal rotation of the hip. The flexion force was generally applied by the delivering mother pulling on her own thighs, bringing the knees toward the chest. In contrast, the internal rotation torque was applied by an assistant (husband, relative, or health care professional) pulling outward on the foot or ankle.

All 10 postpartum women presented with signs and symptoms of labral tears, which were subsequently confirmed with arthroscopy and surgically repaired. Institutional review board approval was obtained for collection of all patient data through Advocate Good Samaritan Hospital in Downer's Grove, Illinois.

All patients were evaluated preoperatively and at 4 months postoperatively using the modified Harris hip score,<sup>9</sup> a validated outcomes instrument to measure hip pain and function. In addition, all patients were asked at their most recent visit whether they were satisfied with the outcome of the surgery.

## RESULTS

All 10 patients were initially treated nonoperatively with oral pain medications, injections, and physical therapy without significant long-term relief. Each patient subsequently underwent diagnostic arthroscopy at a minimum of 6 months after delivery. In all cases, labral pathology was directly visualized arthroscopically. All labral tears were treated with either labral refixation or labral débridement. In cases involving bony morphology of impingement, additional acetabuloplasty or femoroplasty was performed to prevent future femoroacetabular impingement. Although it is impossible to know for sure if any patient had pre-existing hip pathology, none of the patients had any symptoms of hip pain before pregnancy, and thus any pathology that may have existed was clinically silent until pregnancy.

Each patient experienced relief of symptoms within 4 months after the procedure. All patients were satisfied with surgery, and all patients had

improvement in the modified Harris hip score. The average preoperative modified Harris hip score was 53.1 and the average postoperative modified Harris hip score was 84.3 ( $P < .001$ ). Three of the 10 patients have undergone subsequent vaginal delivery without complication.

## DISCUSSION

In very recent years, there has been a dramatic increase in the diagnosis of hip injuries such as labral tears.<sup>8,10-12</sup> This increase has been attributed to the incremental advances in understanding of such hip injuries as well as greatly improved diagnostics (physical examination tests, radiographic views, and high-resolution magnetic resonance angiography). As of now, the magnitude of the problem is largely unknown. Only a subset of women postpartum may ever present for orthopedic evaluation, and therefore we cannot accurately assess the denominator. However, it is known that acetabular labral tears are a very common cause of hip pain in the young population and may be the most common injury that necessitates hip arthroscopy.<sup>11</sup>

On inspection, the clinician should pay attention to how the patient describes and localizes the pain. With deep hip pathology, the patient will often exhibit a "C-sign."<sup>13</sup> The patient cups the lateral thigh above the greater trochanter with the thumb posterior and the fingers gripping the anterior groin (Fig. 5). This pain is often associated with hip flexor weakness in the affected leg. The quality of the pain ranges from a constant dull ache to intermittent episodes of sharp pain. The pain is generally aggravated by activity including weightbearing, twisting or pivoting motions, and stairs

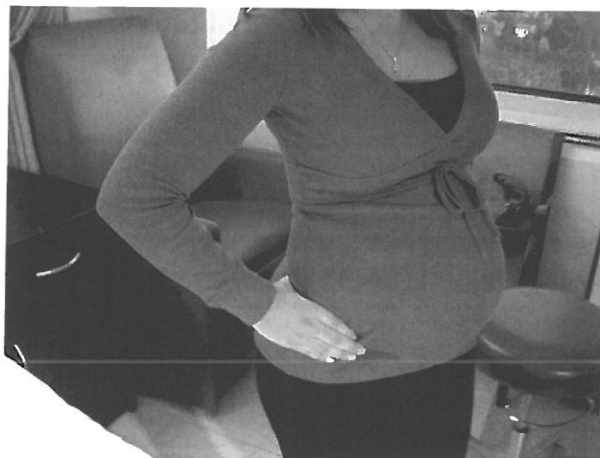

Fig. 5. Demonstration of the "C-sign" indicated intra-articular pathology.

Brooks. Postpartum Labral Tears. *Obstet Gynecol* 2012.

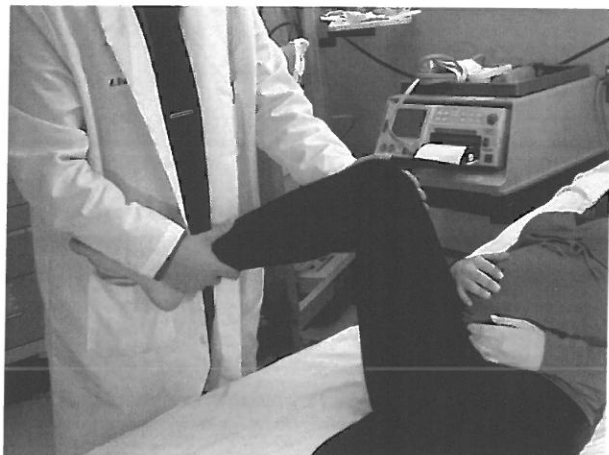

as well as prolonged standing, walking, or sitting. Rest and nonsteroidal anti-inflammatory drugs will temporarily alleviate the pain in most cases. Mechanical symptoms including a catching or locking sensation are often also present.

Palpation may yield point tenderness in various areas including the greater trochanter, the psoas, the rectus femoris, or the pubic symphysis, but palpation is often not specific for the diagnosis of labral pathology. Hip range of motion will often be decreased in flexion, abduction, internal rotation, and external rotation. Range of motion should be compared with the contralateral side to determine this decrease.

Several special maneuvers can help in the diagnosis of an acetabular labral tear, and these special maneuvers were positive in our 10 patients. The log roll of the hip is performed in the supine position by externally and internally rotating the extended hip and knee. Pain in the groin area constitutes a positive log roll, which is highly suspicious for intra-articular pathology.<sup>13</sup>

Additional tests include the “impingement test,” the Patrick FABER (Flexion ABduction External Rotation) test, and the McCarthy test; all four special maneuvers can help diagnose impingement or a labral tear. The impingement test is performed with forced flexion, adduction, and internal rotation (Fig. 6). A positive test occurs when the patient’s presenting pain is reproduced. This maneuver may be uncomfortable without any pathology, so the clinician must ask the patient to distinguish the presenting pain from common discomfort with the impingement test.<sup>12</sup>



**Fig. 6.** Demonstration of the impingement test (forced flexion, adduction, and internal rotation).

Brooks. *Postpartum Labral Tears*. *Obstet Gynecol* 2012.

The FABER test is performed in the supine position by having the patient make a figure-of-four with the ankle of the affected extremity lying on the hip of the unaffected side (flexion, abduction, and external rotation). Lateral pain indicates lateral impingement.<sup>12</sup> Passively extending and flexing the hip in the figure-of-four position can further distinguish impingement as the cause. If the pain is specifically reproduced in flexion, impingement is more likely. Posterior pain may indicate sacroiliac joint pathology, which is more consistent with pregnancy-related posterior pelvic pain.

Lastly, the McCarthy test involves maximally flexing both hips and then extending the affected hip in external rotation and then again in internal rotation. Reproduction of the patient’s pain with this maneuver is a positive McCarthy test.<sup>14</sup> If elements of the history or physical are positive, referral to an orthopedic surgeon for additional work-up and treatment is appropriate.

If this history and physical is suspicious for labral pathology, imaging is an appropriate next step in the diagnosis. If initial nonoperative management has not resulted in improvement, referral to an orthopedic surgeon would be appropriate before obtaining any advanced imaging.

Plain radiography will not diagnose a labral tear alone, but a standard anteroposterior radiograph of the pelvis and cross-table lateral radiograph of the affected hip can help compare both sides and analyze the morphology of the acetabulum, the femoral head, and the femoral neck. Modified Dunn views (hip flexed 90° and abducted 20°) can better detect cam lesions.<sup>15</sup>

Magnetic resonance arthrography in concert with a detailed history and physical examination can help evaluate the soft tissue of the hip including the labrum.<sup>16</sup> Magnetic resonance arthrography is only useful when a reasonable suspicion of hip pathology exists. Notably, plain magnetic resonance imaging without intra-articular contrast is of limited diagnostic use for detection of labral tears. For this reason, the authors highly recommend magnetic resonance arthrography.

A diagnostic injection is another highly sensitive procedure for differentiating intra-articular from extra-articular pathology. A local anesthetic is injected into the affected hip. Temporary relief confirms intra-articular pathology.<sup>17</sup>

We have identified a subset of women who develop hip pain during pregnancy or delivery caused by a labral tear. Although there is sparse reference to this problem in the literature, we believe that the advances in diagnosis and treatment of hip pathology



have increased our awareness and thus diagnosis of labral tear and that our case series reflects this increased awareness.

We can posit several theories as to why pregnant women may be at increased risk for labral pathology. Increased joint laxity during pregnancy has been previously theorized as a cause of sacroiliac joint, pubic symphysis, or lumbar spine pathology and may play a role in pregnancy-related labral tears. The cause of this increased joint laxity is debatable (increased relaxin compared with other hormonal changes), but the presence of increased joint laxity is generally accepted.<sup>1</sup> Additionally, the increased axial load through the hip because of increased weight during pregnancy is a possible contributing factor to labral tears. As a result of such changes, labral tear may begin at any time during pregnancy. Although these factors may increase the risk of labral tears as well as other pregnancy-related orthopedic problems, they are physiologic changes of pregnancy that are likely unavoidable.

In contrast, the position of delivery can be controlled, and thus labral tears that occur during delivery may be avoidable with simple modifications. Flexion and internal rotation of the hip is generally accepted as a position of labral impingement. By bringing the hips to the extreme of flexion and internal rotation during delivery, a woman may cause a forceful pinching of the labrum, which may result in a labral tear. A well-meaning partner, nurse, or assistant may attempt to assist the delivering mother by pulling the ankle (Fig. 7). In so doing, they may inadvertently pull the ankle laterally, which increases the internal rotation of the hip and thus increases the

pinch on the labrum. This mechanism of injury can be avoided by ensuring that during delivery, the distal extremities, including the ankle, are free from the hold of any other person, which will allow the hip to externally rotate in flexion and likely avoid acute, forceful impingement (Fig. 8).

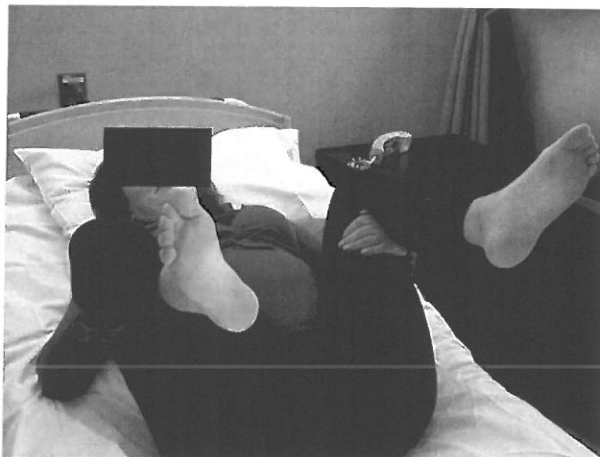
In the event that labral injury causes persistent pain in the postpartum woman, a trial of nonoperative management is the first-line therapy. Physical therapy should focus on activity modification and limiting athletic activity. Passive range of motion and stretching exercises during physical therapy are not advised, because they may worsen the pathology. Nonsteroidal anti-inflammatory drug use is another important component of nonoperative management. All patients with labral tears at our institution receive a diagnostic injection to confirm the intra-articular nature of the pain. Although an attempt at physical therapy, injection, and medications is important, nonoperative management may fail in the presence of irreversible structural damage to the labrum, especially when accompanied by anatomic predilection toward impingement. However, nonoperative management is sometimes effective, and surgery can be avoided in those patients.<sup>18</sup>

When hip pain persists more than 6 months postpartum, and nonoperative management fails, open or arthroscopic surgical intervention may be indicated. In our series, arthroscopic labral repair was successful in treating the persistent symptoms and may delay or prevent the long-term consequence of early-onset arthritis. Once the labrum has torn and the underlying cartilage has avulsed from the acetabulum,



**Fig. 7.** Demonstration of a well-meaning assistant inadvertently placing the patient in a position of impingement by not allowing the hip to externally rotate.

Brooks. *Postpartum Labral Tears. Obstet Gynecol* 2012.



**Fig. 8.** Demonstration of a delivery position that allows the hip to externally rotate freely.

Brooks. *Postpartum Labral Tears. Obstet Gynecol* 2012.



there will be continued irregular contact leading to worsening pathology, a decrease in cartilage, and eventual arthritis.<sup>19,20</sup> Surgical management consists of open or arthroscopic labral refixation, labral débridement, and, when necessary, femoroplasty or acetabuloplasty to correct any cam or pincer lesions, respectively.<sup>21</sup> The procedure is generally well tolerated and the recovery is relatively short.

Our case series demonstrates that labral pathology can be a cause of hip pain in postpartum women. Some of these injuries may be associated with unavoidable physiologic changes of pregnancy, including weight gain and ligamentous laxity. In contrast, the incidence of hip injuries during delivery may be decreased with simple modifications of positioning. By not pulling on the ankle during delivery, the hip can freely externally rotate, helping to avoid the position of hip impingement. If hip pain persists more than 6 months after pregnancy and fails to improve with nonoperative measures, referral to an orthopedic surgeon may be appropriate. In this setting, surgical treatment can provide positive outcomes. Future collaborative studies between orthopedic surgeons and obstetricians will be necessary to determine the overall incidence and associated risk factors (weight gain, gravida, para, duration of labor, use of epidural) of peripartum hip injuries.

## REFERENCES

- Smith MW, Marcus PS, Wurtz LD. Orthopedic issues in pregnancy. *Obstet Gynecol Surv* 2008;63:103–11.
- Ronchetti I, Vleeming A, Van Wingerden JP. Physical characteristics of women with severe pelvic girdle pain after pregnancy. *Spine (Phila Pa 1976)* 2008;33:E145–51.
- Noren L, Ostgaard S, Johansson G, Ostgaard HC. Lumbar back and posterior pelvic pain during pregnancy: a 3-year follow-up. *Eur Spine J* 2002;11:267–71.
- Nilsson-Wikmar L, Harms-Ringdahl K, Pilo C, Pahlbäck M. Back pain in women post-partum is not a unitary concept. *Physiother Res Int* 1999;4:201–13.
- Hansen A, Jensen DV, Larsen EC, Wilken-Jensen C, Kaae BE, Frølich S, et al. Postpartum pelvic pain—the ‘pelvic joint syndrome’: a follow-up study with special reference to diagnostic methods. *Acta Obstet Gynecol Scand* 2005;84:170–6.
- Gutke A, Ostgaard HC, Oberg B. Association between muscle function and low back pain in relation to pregnancy. *J Rehabil Med* 2008;40:304–11.
- Baker J, McGuire C, Mulhall K. Acetabular labral tears following pregnancy. *Acta Orthop Belg* 2010;76:325–8.
- Parvizi J, Leunig M, Ganz R. Femoroacetabular impingement. *J Am Acad Orthop Surg* 2007;15:561–70.
- Byrd J, Jones K. Prospective analysis of hip arthroscopy with 2-year follow-up. *Arthroscopy* 2000;16:578–87.
- Kuhlman G, Domb B. Hip impingement: identifying and treating a common cause of hip pain. *Am Fam Physician* 2009;80:1429–34.
- Botser IB, Smith TW Jr, Nasser R, Domb BG. Open surgical dislocation versus arthroscopy for femoroacetabular impingement: a comparison of clinical outcomes. *Arthroscopy* 2011;27:270–8.
- Domb BG, Brooks AG, Byrd JW. Clinical examination of the hip joint in athletes. *J Sport Rehabil* 2009;18:3–23.
- Byrd JW. Physical examination. In: Byrd JW, ed. *Operative hip arthroscopy*. New York (NY): Springer; 2005.
- McCarthy JC. Hip arthroscopy: when it is and when it is not indicated. *Instr Course Lect* 2004;53:615–21.
- Meyer D, Beck M, Ellis T, Ganz R, Leunig M. Comparison of six radiographic projections to assess femoral head/neck asphericity. *Clin Orthop Relat Res* 2006;445:181–5.
- Mintz DN, Hooper T, Connell D, Buly R, Padgett DE, Potter HG. Magnetic resonance imaging of the hip: detection of labral and chondral abnormalities using noncontrast imaging. *Arthroscopy* 2005;21:385–93.
- Byrd JW, Jones KS. Diagnostic accuracy of clinical assessment, magnetic resonance arthrography, and intra-articular injection in hip arthroscopy patients. *Am J Sports Med* 2004;32:1668–74.
- Hunt D, Prather H, Hayes M, Clohisy J. Clinical outcomes analysis of conservative and surgical treatment of patients with clinical indications of prearthritic, intra-articular hip disorders. *PM R* 2012;4:479–87.
- McCarthy J, Noble PC, Schuck MR, Wright J, Lee J. The Otto E. Aufranc Award: The role of labral lesions to development of early degenerative hip disease. *Clin Orthop Relat Res* 2001;393:25–37.
- Ganz R, Parvizi J, Beck M, Leunig M, Notzli H, Siebenrock KA. Femoroacetabular impingement: a cause for osteoarthritis of the hip. *Clin Orthop Relat Res* 2003;417:112–20.
- Fry R, Domb BG. Labral base refixation in the hip: rationale and technique for an anatomic approach to labral repair. *Arthroscopy* 2010;29:S81–9.

