

# Labral Penetration Rate in a Consecutive Series of 300 Hip Arthroscopies

Benjamin Domb,<sup>\*†‡</sup> MD, Bryan Hanypsiak,<sup>§</sup> MD, and Itamar Botser,<sup>†‡</sup> MD  
*Investigation performed at Hinsdale Orthopaedic Associates, Hinsdale, Illinois*

**Background:** Intraoperative labral injury during the establishment of the first portal in hip arthroscopy has been reported to be as high as 20%.

**Purpose:** The purpose of the study was to prospectively identify the incidence of acetabular labral injuries that occurred while using a current technique for the establishment of portals during hip arthroscopy.

**Study Design:** Case series; Level of evidence, 4.

**Methods:** Between the years 2008 and 2010, data were prospectively collected for all patients undergoing hip arthroscopic surgery. Patients with previous labral resection or Tonnis grade greater than 1 were excluded. Patients were positioned supine, traction was applied, and portals were established. The anterolateral portal was created first by venting the joint with a spinal needle and then re-entering the joint with the same needle with the bevel side facing the labrum. Next, the midanterior portal was created under vision. A thorough examination of the acetabular labrum was conducted arthroscopically through multiple viewing portals, and labral injuries related to the establishment of portals were identified and noted.

**Results:** A total of 300 patients were included in the study; only 2 patients (0.67%) suffered intraoperative labral injuries at the study period. One injury occurred during revision arthroscopy, while the second involved a hyperplastic labrum in a dysplastic hip. No patient with normal hip morphological characteristics undergoing a hip arthroscopy suffered a labral tear as a result of portal placement.

**Conclusion:** The incidence of iatrogenic labral injury during hip arthroscopy can be as low as 0.67% when using the described technique.

**Keywords:** hip arthroscopy; iatrogenic labral injury; intraoperative labral injury; portal establishment; arthroscopic safe access

The labrum is thought to be important in multiple aspects of the biomechanics of the hip, including the regulation of flow of synovial fluid, maintenance of the suction seal, stability, and load bearing.<sup>1,12-15</sup> Biomechanical studies have suggested that a functional labrum slows cartilage consolidation through its hydrostatic effects and therefore may serve a protective role for the articular cartilage.<sup>14</sup> For these reasons, it is thought that the labrum should be preserved when possible. Labral tears may result from a variety of causes, such as femoroacetabular impingement and

degenerative changes.<sup>16,21</sup> However, they may also occur as a result of iatrogenic injury during portal placement.

Intraoperative injury to the acetabular labrum (Figure 1) during hip arthroscopy has been reported with a frequency as high as 20%.<sup>3</sup> The deep and tight anatomy of the hip presents unique difficulties in arthroscopic access, which may make an intraoperative injury more likely than in other large joints. These injuries occur most commonly because of labral penetration during establishment of the initial portal. The first portal in hip arthroscopy is normally established by introducing a spinal needle into the joint under fluoroscopic guidance and then using an “over-the-guidewire” technique to introduce the arthroscope. While fluoroscopy is of great assistance in locating the space between the femur and acetabular rim, it does not provide visualization of the labrum and therefore cannot directly ensure avoidance of labral penetration. If the spinal needle is placed through the labrum, the subsequent insertion of a guidewire, followed by the arthroscope cannula, will follow the same track. This will cause a tear of the labrum at least equal in size to the diameter of the arthroscope cannula. If the arthroscope, in its translabral position, is subsequently moved around by the surgeon in an attempt to gain better visualization, such movement may enlarge the tear of the labrum. Because tears of the

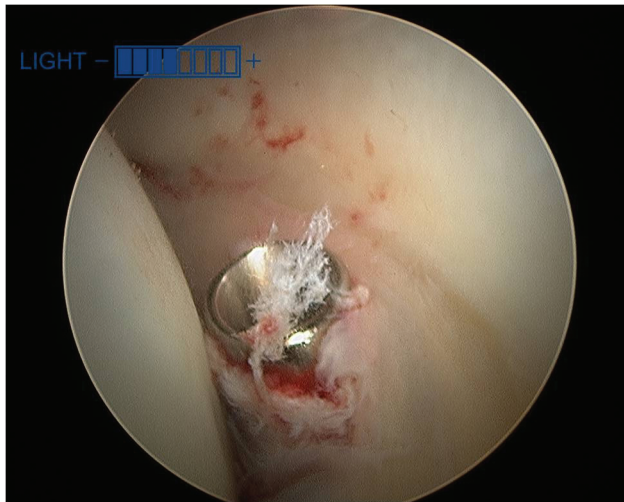
\*Address correspondence to Benjamin Domb, MD, Hinsdale Orthopaedics Associates, 1010 Executive Court, Suite 250, Westmont, IL 60559 (e-mail: dombsteam@gmail.com).

<sup>†</sup>Hinsdale Orthopaedics Associates, Hinsdale, Illinois.

<sup>‡</sup>Stitch School of Medicine, Loyola University Chicago, Maywood, Illinois.

<sup>§</sup>Arthrex Inc, Naples, Florida.

One or more of the authors has declared the following potential conflict of interest or source of funding: Dr Hanypsiak is an employee of Arthrex Inc. Dr Domb consults for and has received research support from Arthrex Inc.



**Figure 1.** Penetration of a metal cannula (Smith & Nephew, London, England) through the acetabular labrum from the anterolateral portal during hip arthroscopy. View from the midlateral portal.

labrum can lead to accelerated wear of the articular cartilage and early degenerative osteoarthritis,<sup>2,10,19</sup> theoretically, any surgeon should avoid intraoperative labral injuries as much as possible.

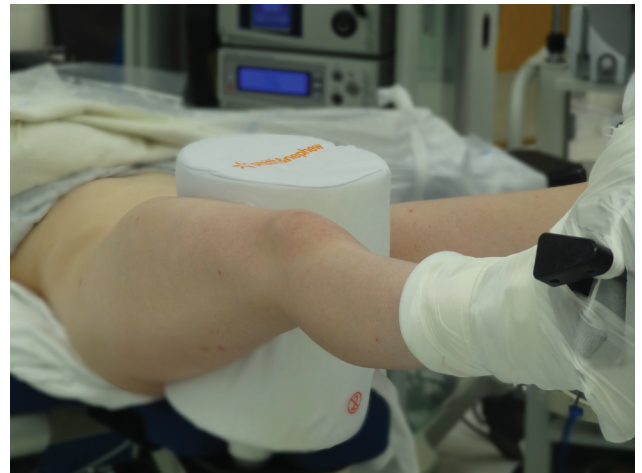To help reduce the frequency of intraoperative labral injuries, we have been using a stepwise technique for the safe access and establishment of portals in hip arthroscopy (see the Video Supplement, available in the online version of this article at <http://ajs.sagepub.com/supplemental/>). The purpose of the study was to prospectively assess the incidence of labral penetration using the current technique for the establishment of portals during hip arthroscopy. Our hypothesis was that a systematic use of this access technique during hip arthroscopy would show a low incidence of intraoperative labral injury.

## MATERIALS AND METHODS

From 2008 to 2010, data were prospectively collected for all patients undergoing hip arthroscopic surgery in our institution. Patients who had undergone previous labral excision were excluded. All surgeries were performed with the patient in the supine position by the senior author (B.D.) using a well-padded perineal post.<sup>6</sup> The operative extremity was positioned in maximum adduction, limited only by the post, flexed 15°, and placed in internal rotation (Figure 2). Traction was applied to break the suction seal, and adequate joint distraction of 8 to 12 mm was achieved. In all cases, traction time was limited to 2 hours to prevent traction-related complications.<sup>4,7,11</sup>

### Technique

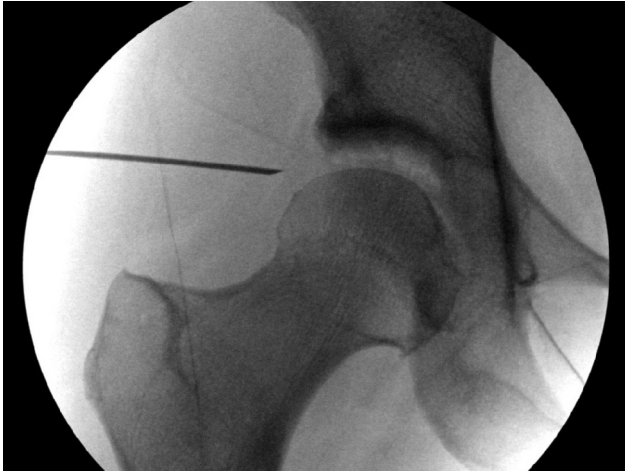
With the hip distracted and positioned as described above, the location of the anterolateral portal was palpated just



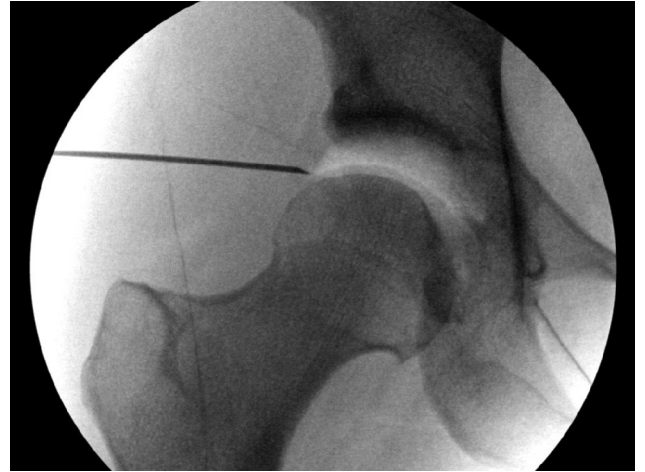**Figure 2.** The operative extremity (left) is positioned in adduction, the hip flexed 20°, and placed in internal rotation. A large perineal post is used to protect the pudendal nerve and genitalia during surgery.

proximal and anterior to the greater trochanter. Once the starting location was acknowledged using fluoroscopy, a 14-gauge spinal needle (Arthrex Inc, Naples, Florida) was laid on the skin to determine the angle of approach. The angle of approach was determined according to the length of the femoral neck, the neck shaft angle, and the lateral coverage of the acetabulum. Moreover, because dysplastic hips usually have wider labrums, the entry point in those joints was planed more distally. After this, the needle was inserted through the anterolateral portal, aiming toward the inferior part of the joint space with the bevel facing toward the femoral head (Figure 3). This bevel orientation during initial entry was intended to minimize the likelihood of femoral head cartilage scuffing. The needle was advanced until a “pop” was felt as it exited the articular side of the capsule. The stylet was removed, venting the joint and creating an air arthrogram (Figure 4). This resulted in neutralization of negative intra-articular pressure that was created by the traction; hence, increased distraction and distension of the joint capsule occurred and were seen fluoroscopically. The stylet was then reinserted and the needle withdrawn outside of the capsule. The needle was considered to be out of the joint only with the aid of confirmation by fluoroscopy (Figure 5). Now that maximal distraction had been achieved by venting the joint, the needle could be reinserted. During this entry step, the bevel was held facing the labrum to minimize the likelihood of labral penetration, and the needle was aimed toward the most distal part of the air arthrogram. The needle was gently advanced until a “pop” was felt or fluoroscopy indicated that the needle tip was intracapsular (Figure 6). At this point, the needle was rotated 180° to turn the bevel of the needle toward the articular cartilage of the femoral head. The needle was then advanced into the joint, bevel down, preventing damage to the articular cartilage of the femoral head (Figure 7).

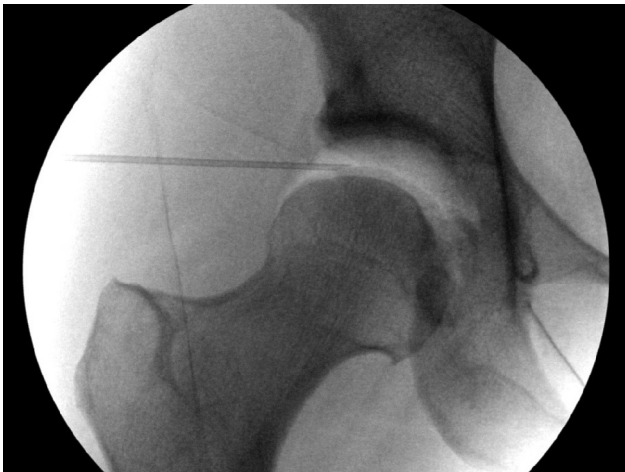The stylet was then withdrawn, and a nitinol wire was placed through the needle. The wire was advanced until it



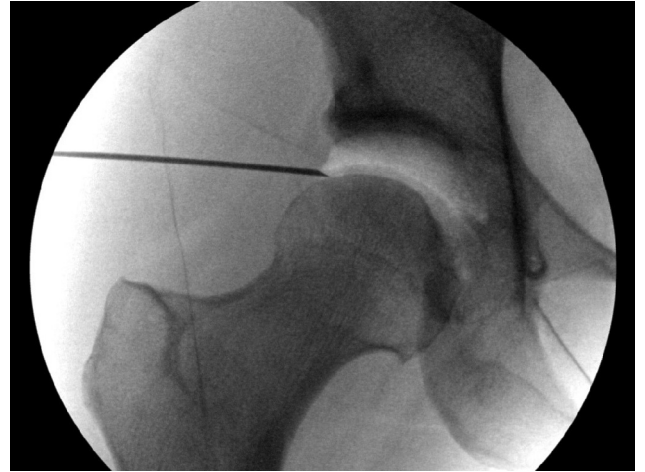
**Figure 3.** A 14-gauge spinal needle is introduced at the site of the anterolateral portal and advanced with the bevel facing toward the femoral head. The angle of approach is toward the inferior extent of the joint space.



**Figure 5.** The stylet is reinserted and the needle withdrawn outside the capsule. The needle tip is clearly visualized outside of the capsule.



**Figure 4.** The needle is advanced until it penetrates the capsule. The stylet is removed to vent the joint, creating an air arthrogram and increasing distraction.



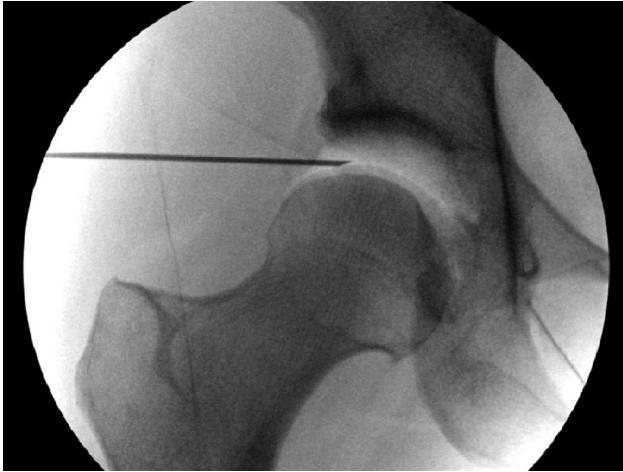
**Figure 6.** With the bevel side of the needle facing toward the labrum, the needle is gently advanced until a "pop" is felt or the tip is at least 1 mm inside the capsule as demonstrated. This step minimizes the likelihood of labral penetration.

made contact with the medial acetabular wall (Figure 8). The arthroscope sheath with a cannulated obturator was then advanced over the wire until it contacted the hip capsule (Figure 9). Care was taken to aim the tip of the obturator slightly superiorly to avoid scuffing the femoral head, and the obturator was advanced through the capsule until a "pop" was felt (Figure 10). The guidewire was retracted slightly from the acetabular wall to prevent bending or breakage and to expedite removal. The obturator and guidewire were then withdrawn, and the arthroscope was entered into the joint through the arthroscope sheath.

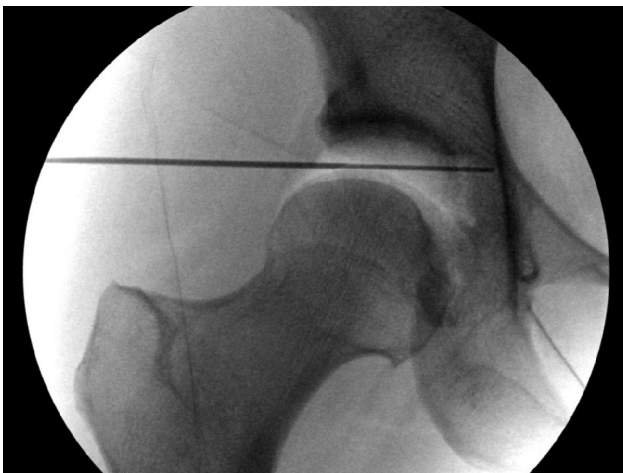Further portal placement was controlled arthroscopically. Once the arthroscope was inserted through the anterolateral portal, dry arthroscopy of the hip joint was then undertaken, as bleeding from the portal will often obscure

vision in a fluid-filled environment. For the assessment of the midanterior portal, the 70° arthroscope was used to identify the anterior capsule in the triangular region between the labrum and the curve of the femoral head. This marks the intra-articular access point for the midanterior portal. A spinal needle was introduced into the joint, and direct visualization with the arthroscope was used to ensure the needle did not penetrate the labrum. Once the needle was positioned appropriately, the stylet was removed, a nitinol wire was inserted, and the portal was dilated under direct visualization (Figure 11). A capsulotomy was then performed, and a cannula was inserted if necessary. Diagnostic arthroscopy was routinely performed after establishment of these 2 portals. A





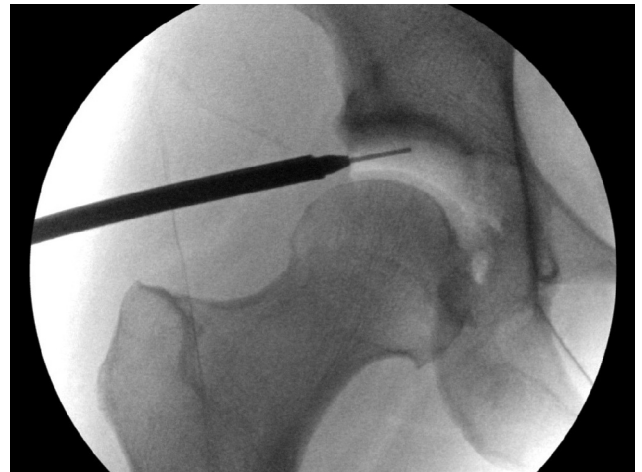**Figure 7.** The needle is rotated 180° and advanced into the joint with the flat part facing toward the femoral head's articular cartilage, preventing scuffing of the femoral head.



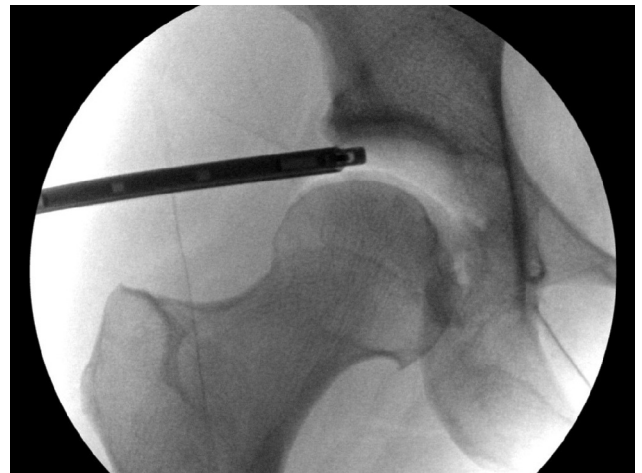**Figure 8.** A nitinol wire is then passed through the needle until it makes contact with the acetabular wall. The needle is then withdrawn and the wire left in place.

circumferential examination of the entire labrum and central compartment was performed with the arthroscope in the anterolateral portal. The portals were then switched, and the diagnostic arthroscopy was repeated with the arthroscope in the midanterior portal. Care was taken to examine the site of entry of the first (anterolateral) portal when viewing from the midanterior portal to ensure that no labral penetration had occurred.

In our series, a thorough arthroscopic examination of the labrum was conducted after the establishment of portals. This examination included visualization from both the anterolateral and midanterior portals, allowing visualization of the entry site of the first (anterolateral) portal and of the cartilage surfaces around each of the portal entry sites. Labral injuries related to the establishment of portals were identified and noted.



**Figure 9.** The arthroscope sheath with the cannulated obturator is passed over the nitinol wire. The nitinol wire is pulled back 15 mm to avoid wire breakage. After the arthroscope sheath and obturator penetrate the capsule, the surgeon moves his hand toward the patient's foot in order to advance the obturator while angling superiorly to avoid scuffing the femoral head.

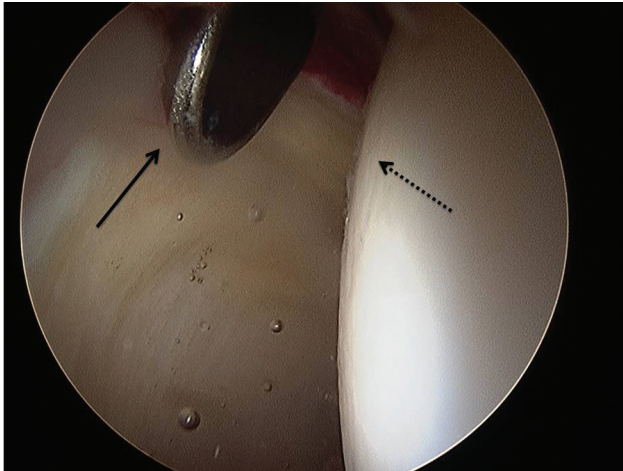


**Figure 10.** The arthroscopic camera is viewed in the joint through the anterior lateral portal, and between the femoral head and the acetabulum.

## RESULTS

A total of 300 cases were included in the study; only 2 (0.67%) suffered from intraoperative labral injuries. One injury occurred during revision arthroscopy, while the second involved a hypertrophic labrum in a dysplastic hip. Both injuries occurred during the establishment of the anterolateral portal. No patient with normal hip morphological characteristics undergoing a hip arthroscopy suffered a labral tear as a result of portal placement.

In general, during the first penetration to the joint, there may have been punctures of the labra with the

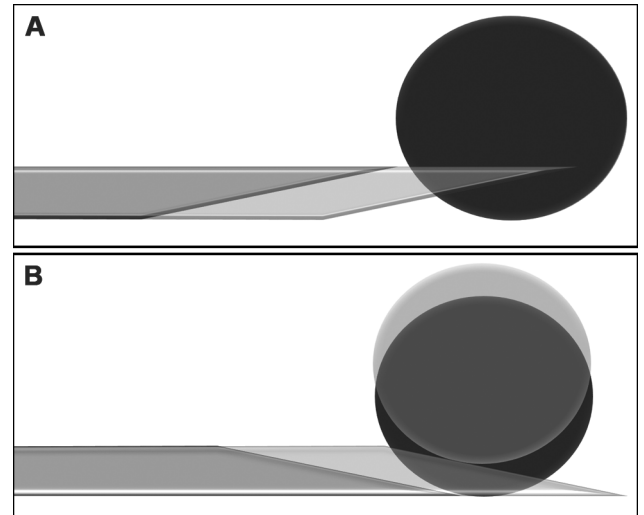


**Figure 11.** Intra-articular view of the hip showing appropriate placement of the metal cannula from the midlateral portal through the hip capsule, between the acetabular labrum (black arrow) and femoral head (dotted arrow). View from the anterolateral portal.

needle. However, because this injury is minimal in nature, damage is rarely seen from within the joint, and we could not estimate its incidence.

## DISCUSSION

The acetabular labrum is a peripheral articular fibrocartilage complex that adds depth to joint geometry and increases articular contact.<sup>1</sup> The labrum has been shown to increase the articulating surface by 22% and acetabular volume by 33%.<sup>22</sup> When the joint is unloaded, synovial fluid flows freely throughout the central compartment. In the weightbearing phase, the labrum seals synovial fluid between the femoral head and acetabulum, driving it into the articular cartilage and providing nutrition and lubrication.<sup>17</sup> The labrum, which also possesses proprioceptive and nociceptive properties, guides the femoral head into the joint under compressive loading by establishing joint contact at the periphery.<sup>1,18</sup> When peripheral contact is established first, the labrum is able to seal the pressurized synovial fluid in the joint because of its high resistance to radial interstitial flow. The pressurized synovial fluid transmits the load within the cartilage layers to the underlying subchondral bone and slows the expression of fluid out of the cartilage matrix, reducing the solid contact stresses on the cartilage.<sup>12,14,15</sup> The egress of synovial fluid out of the cartilage matrix under compression is known as consolidation. Ferguson et al<sup>14</sup> showed that labral excision in a cadaveric model increased the rate of consolidation by 22%. This rate increased to 48% in joints identified as having a closer fit between the labrum and femoral head. A poroelastic finite element model showed a 40% increase in the consolidation rate with labral excision.<sup>13</sup> It was emphasized in this study that the function of the labrum in this capacity is dependent on the contact between the labrum and the femoral head.



**Figure 12.** Illustration of the “needle safe side” principle. (A) The sharp side is pointing toward the object; as the needle is advanced, it is penetrating the object. (B) The bevel side is pointing toward the object; as the needle is advanced, the object is pushed away.

Loss of the labral seal has also been shown to destabilize the hip in a cadaveric model.<sup>9</sup> Femoral head motion increased with both venting of the capsule and creation of a labral tear. Venting of the capsule and subsequent labral injury caused 43% and 60% decreases, respectively, in traction required to create 3 mm of joint distraction. This demonstrates that both the capsular and labral integrity contribute to the vacuum seal of the joint.

As our understanding of the function of the labrum continues to grow, the effect of damage to the labrum becomes clear: loss of synovial fluid during loading, microinstability of the femoral head, increased articular cartilage contact pressures, and the development of early osteoarthritis. Preservation of the labrum is therefore imperative, and iatrogenic injuries must be avoided at all costs. The greatest risk of labral damage may be during placement of the first arthroscopic portal, which is established under fluoroscopy, without the aid of direct intra-articular visualization. Generally, this portal is established by entering the joint with a spinal needle, followed by an “over-the-guidewire” technique for introduction of the arthroscope. Using this technique, if the spinal needle is placed through the labrum, the arthroscope sheath will inevitably follow the same path and puncture the labrum. The diameter of the sheath penetrating the labrum can cause a significant labral injury. In addition, if the translabral position of the arthroscope is not immediately recognized by the surgeon, subsequent attempts to move the arthroscope within the joint will cause enlargement of the labral tear.

Few studies have specifically examined the frequency of labral penetration during access in hip arthroscopy. Three of the largest studies reporting complications of hip arthroscopy did not comment on rates of labral penetration.<sup>5,8,20</sup> Badylak and Keene<sup>3</sup> reported labral penetration occurred in 50 of 250 hip arthroscopy procedures (20%) and

noted that the presence or absence of labral penetration did not have any significant effect on clinical outcome. However, all procedures performed were labral debridements in which the damaged area of the labrum may have been resected, thus abrogating the effect of the intraoperative labral injury. As evidence develops for the advantages of labral preservation, lower rates of labral intraoperative injury are desirable.

The current technique employs 2 basic principles to keep the labrum intact. The first is to vent the joint with the spinal needle and then to withdraw and re-enter the joint (Figure 1). Venting the joint releases the negative intra-articular pressure created by the traction that was applied earlier; hence, the capsule expands and potentially retracts the labrum outside. Moreover, because the negative pressure was released, the joint is distracted more, leaving more space between the labrum and the femoral head. The second principle is to consider the bevel side of the spinal needle as the "safe side"; tissues on the bevel side are pushed away and not penetrated (Figure 12). In this manner, further damage to the labrum or the cartilage is avoided.

By following the current technique described here for establishing and maintaining access to the joint, we were able to reduce the incidence of intraoperative injury to the labrum to 0.67%. Of the 2 labral penetrations that occurred in the 300 cases studied, one occurred in a revision case where the labrum was scarred to the capsule, and the second occurred in a dysplastic hip with a hyperplastic labrum. No labral penetrations occurred in hips with a normal labral shape. It is our recommendation that this technique be followed routinely for establishing portals in hip arthroscopy.

The study has 2 principal shortcomings; the first is the fact that subjective assessment of the labral penetration by the operating surgeon was the only outcome measure. The second limitation was the lack of a control group; the study had only one group on which only one technique was used.

With the proper technique, the risk of iatrogenic labral injury can be reduced to less than 1% of cases, which may aid in labral preservation and may lead to improved postoperative outcomes.

## REFERENCES

1. Adeeb SM, Sayed Ahmed EY, Matyas J, Hart DA, Frank CB, Shrive NG. Congruency effects on load bearing in diarthrodial joints. *Comput Methods Biomech Biomed Engin*. 2004;7(3):147-157.
2. Altenberg AR. Acetabular labrum tears: a cause of hip pain and degenerative arthritis. *South Med J*. 1977;70(2):174-175.
3. Badylak JS, Keene JS. Do iatrogenic punctures of the labrum affect the clinical results of hip arthroscopy? *Arthroscopy*. 2011;27(6):761-767.
4. Brumback RJ, Ellison TS, Molligan H, Molligan DJ, Mahaffey S, Schmidhauser C. Pudendal nerve palsy complicating intramedullary nailing of the femur. *J Bone Joint Surg Am*. 1992;74(10):1450-1455.
5. Byrd JW. Complications associated with hip arthroscopy. In: Byrd JW, ed. *Operative Hip Arthroscopy*. New York: Thieme; 1998:171-176.
6. Byrd JW. Hip arthroscopy: the supine position. *Clin Sports Med*. 2001;20(4):703-731.
7. Byrd JW, Chern KY. Traction versus distension for distraction of the joint during hip arthroscopy. *Arthroscopy*. 1997;13(3):346-349.
8. Clarke MT, Arora A, Villar RN. Hip arthroscopy: complications in 1054 cases. *Clin Orthop Relat Res*. 2003;406:84-88.
9. Crawford MJ, Dy CJ, Alexander JW, et al. The 2007 Frank Stinchfield Award: the biomechanics of the hip labrum and the stability of the hip. *Clin Orthop Relat Res*. 2007;465:16-22.
10. Dorrell JH, Catterall A. The torn acetabular labrum. *J Bone Joint Surg Br*. 1986;68(3):400-403.
11. Elsaidi GA, Ruch DS, Schaefer WD, Kuzma K, Smith BP. Complications associated with traction on the hip during arthroscopy. *J Bone Joint Surg Br*. 2004;86(6):793-796.
12. Ferguson SJ, Bryant JT, Ganz R, Ito K. The acetabular labrum seal: a poroelastic finite element model. *Clin Biomech (Bristol, Avon)*. 2000;15(6):463-468.
13. Ferguson SJ, Bryant JT, Ganz R, Ito K. The influence of the acetabular labrum on hip joint cartilage consolidation: a poroelastic finite element model. *J Biomech*. 2000;33(8):953-960.
14. Ferguson SJ, Bryant JT, Ganz R, Ito K. An in vitro investigation of the acetabular labral seal in hip joint mechanics. *J Biomech*. 2003;36(2):171-178.
15. Ferguson SJ, Bryant JT, Ito K. The material properties of the bovine acetabular labrum. *J Orthop Res*. 2001;19(5):887-896.
16. Ganz R, Parvizi J, Beck M, Leunig M, Notzli H, Siebenrock KA. Femoroacetabular impingement: a cause for osteoarthritis of the hip. *Clin Orthop Relat Res*. 2003;417:112-120.
17. Greenwald AS, O'Connor JJ. The transmission of load through the human hip joint. *J Biomech*. 1971;4(6):507-528.
18. Kim YT, Azuma H. The nerve endings of the acetabular labrum. *Clin Orthop Relat Res*. 1995;320:176-181.
19. McCarthy JC, Noble PC, Schuck MR, Wright J, Lee J. The watershed labral lesion: its relationship to early arthritis of the hip. *J Arthroplasty*. 2001;16(8 Suppl 1):81-87.
20. Sampson TG. Complications of hip arthroscopy. *Clin Sports Med*. 2001;20(4):831-835.
21. Seldes RM, Tan V, Hunt J, Katz M, Winiarsky R, Fitzgerald RH. Anatomy, histologic features, and vascularity of the adult acetabular labrum. *Clin Orthop Relat Res*. 2001;382:232-240.
22. Tan V, Seldes RM, Katz MA, Freedhand AM, Klimkiewicz JJ, Fitzgerald RH Jr. Contribution of acetabular labrum to articulating surface area and femoral head coverage in adult hip joints: an anatomic study in cadavera. *Am J Orthop*. 2001;30(11):809-812.