

Physical Examination of the Hip

INTRODUCTION

As our understanding and treatment of hip pathology improves, a systematic, consistent, and reproducible means of clinically evaluating the hip is imperative. While a limp, groin pain, and limited internal rotation are often indicators of hip pathology,¹ the hip is overlooked as the original source of pain or pathology in 60% of primary hip disorders.² Hip pain can be ambiguous in its nature and origin, and pathologies of the hip and low back interact with one another and are easily confused. Hip problems can stem from disorders of the paravertebral muscles, which cause soft tissue instability and irregular tension on the hip.³ Hip pain can also cause back pain by way of muscle contractures of the iliopsoas and the hamstrings or through secondary leg length discrepancy.¹ A systematic and reproducible physical examination of the hip is therefore a necessity for correct diagnosis as well as longitudinal follow-up.

The hip is a focal point of initiation for running and walking and can bear forces equal to over five times body weight during running or jumping.⁴ Because the hip is almost universally subjected to high loads and extremes of motion during sport, hip pain is a common complaint in athletes. In one study, pathology of the hip accounted for 2.5% of adult athletic injuries and 5% to 9% of high school athletic injuries.⁵ Hip pain is especially frequent in sports such as soccer, ballet, hockey, martial arts, rugby, and running.⁵ A recent study of injuries in the National Basketball Association over 17 years found a total of 1,340 hip-related injuries causing 4,753 games missed.⁶

This chapter will focus on techniques to assess hip pathology in several dimensions: location (intra-articular vs. extra-articular), compartment (posterior, anterior, or lateral), and tissue involved (bony, ligamentous, or musculotendinous). The physical examination will also aid in differentiating between pain originating from the hip and back. This chapter comprises six sections. The first section will describe the patient history, and the subsequent five sections will correspond to the five positions in which the physical examination will be conducted: standing, sitting, supine, lateral, and prone.

PATIENT HISTORY

As with all clinical encounters, a detailed history is essential to the final diagnosis and should begin in a traditional manner with the patient's age, chief complaint, and the presence or absence

of trauma.⁷ Much detail about the hip pain should be elicited, including the location and severity of the pain, time of onset, specific quality, alleviating, aggravating, or associated factors, whether the pain is focal or diffuse. Additionally, similar pains, popping or locking symptoms, night pain, and any accompanying numbness or weakness are important to document. Back pain and hip pain will often coexist, so care should be taken to note the severity of one pain relative to the other. Radicular pain may exist with either hip or lumbar spine pathology and is unreliable as a differentiating factor. However, weakness, numbness, and paresthesias in the lower extremity are suggestive of neural compression, often occurring in the lumbar spine.

An inquiry should also be made into any treatment the patient has had and its effectiveness. This treatment may include pharmaceuticals such as nonsteroidal anti-inflammatory drugs (NSAIDs), physical therapy, or the use of any assistive devices.

To further aid in the diagnosis, the patient's activity level should be delineated. Specifically, the ability to complete activities of daily living, work responsibilities, and higher-impact activities should be documented. Participation in certain sports (running, soccer, ballet, hockey, golf, tennis, martial arts, and rugby) can be important since these sports are often associated with specific hip disorders.^{8,9}

A thorough past medical and family history is critical. Past medical considerations should include hip disorders or dislocation during birth or infancy, past surgeries or major illnesses, and any history of trauma. Family history should include hip dislocations or any hip disorder, degenerative joint disease, rheumatologic disorders, and cancer. Also, the physician should be keenly aware of "red flags" such as fever, malaise, night sweats, weight loss, night pain, intravenous drug use, cancer history, or known immunocompromised state.¹⁰ These red flags may indicate systemic problems, and further diagnostic tests may be necessary. Hip conditions can also be related to general medical conditions within the gastrointestinal, genitourinary, neurological, or vascular systems, making a complete, general physical examination an important component of the hip examination.

PHYSICAL EXAMINATION

Any orthopaedic physical examination should begin with an evaluation of the patient's general appearance, which may provide clues to the source of pain. The patient may then be brought to the standing position for the first portion of the exam.

STANDING

The standing examination consists of four parts: gait, alignment, Trendelenburg test, and the laxity test. Because the hip is essential to walk, hip pathologies will often visibly affect a patient's gait.⁷ Six to eight full strides should be observed from both the frontal and sagittal planes, paying close attention to stride length, internal or external rotation of the foot, pelvic rotation, and the stance phase.¹¹ Any snapping or clicking should be noted since these noises may imply psoas contractures, iliotibial (IT) band tightness, or intra-articular pathology. The patient should be asked to rotate his or her hip to recreate the noise in order to differentiate between internal and external snapping.⁸

One of several types of abnormal gaits related to hip pain including antalgic gait, pelvic wink, Trendelenburg gait, excessive pelvic internal or external rotation, and true or false leg length discrepancies may be noted. An antalgic gait is one during which the patient limps to minimize the stance phase on the painful side thus limiting weight bearing. This gait pattern may indicate pain in the hip, pelvis, or lower back.^{12,13} A pelvic wink is rotation in excess of 40° in the axial plane toward the affected hip when terminally extending the hip. This dysfunction can signify hip flexion contractures when lumbar lordosis or a forward-stooping posture is present or can indicate an internal hip pathology. Trendelenburg gait, or abductor lurch, is characterized by a lurching of the trunk toward the affected side during stance phase. The abductor muscles are responsible for stabilizing the pelvis during stance phase. If those muscles are compromised, the patient will compensate by lurching to the ipsilateral side to prevent the pelvis from sagging. In the case of intra-articular hip pathology, patients will frequently walk with a Trendelenburg gait in order to avoid increased joint reactive forces that occur with abductor contraction. Excessive internal or external rotation of the hip should be noted during the gait examination and will be

[AU1] discussed during the seated examination. Finally, a short leg limp during gait may imply either IT band pathology or true or false [AU2] leg length discrepancy (discussed later).

The alignment portion of the examination focuses on leg length discrepancy and spinal alignment. Several methods exist to assess possible true or false leg length discrepancy, which is especially important if a short leg limp is noted during the gait exam. First, examine the height of the shoulders relative to the ipsilateral iliac crest. Second, assess pelvic tilt, a condition that may indicate leg length discrepancy. Third, measure the distance from the anterior superior iliac spine (ASIS) to the ipsilateral medial malleolus. Differences in these measurements suggest a true leg length discrepancy in which the proportions of the bones are different on each side of the body.¹⁴ If there is a short leg limp but no true leg length discrepancy is noted, conditions such as scoliosis, muscle spasms, or pelvic deformities may contribute.⁸

The assessment of spinal alignment involves inspection from two positions. First, the patient stands in front of the examiner and bends forward while the back is inspected for trunk rotation consistent with scoliosis, a contributing factor in functional leg length discrepancy. Second, the patient is viewed laterally for excessive lumbar lordosis or paravertebral muscle spasms. Hip flexor contractures can cause increased lumbar lordosis, and paravertebral muscle spasms can cause hip pain by placing abnormal tension on the hip.³

The next part of the standing examination is the Trendelenburg test (Fig. 4.1). A positive test consists of sagging of the pelvis

greater than 2 cm while the patient lifts the contralateral leg off the floor. By lifting the right leg, one is testing the left abductor muscles and neural loop, and vice versa. A positive sign therefore suggests incompetence of abductor function. The maneuver should be performed first on the unaffected side to establish a comparative norm.

Finally, laxity can be assessed by checking for hyperextension of the knee and elbow, along with the thumb-to-wrist exam. The thumb-to-wrist exam involves an attempt to touch the anterior forearm with the thumb (Fig. 4.2). A positive thumb-to-wrist exam along with hyperextension of the knee and elbow beyond 5° is suggestive of generalized hyperlaxity of the ligaments.⁹

SITTING

The sitting examination consists of three parts: circulatory, neurological, and rotational. As with all aspects of the physical examination, bilateral evaluation in the seated position is essential. The circulatory examination requires checking the dorsalis, pedis, and posterior tibial pulses and inspecting the skin and lymphatics around the hip. This pulse is absent in 2% to 3% of normal, healthy young adults, so its absence alone would not be sufficient to conclude a vascular pathology.¹⁵ Both sides should be compared for any scarring of the skin or lymphadenopathy.

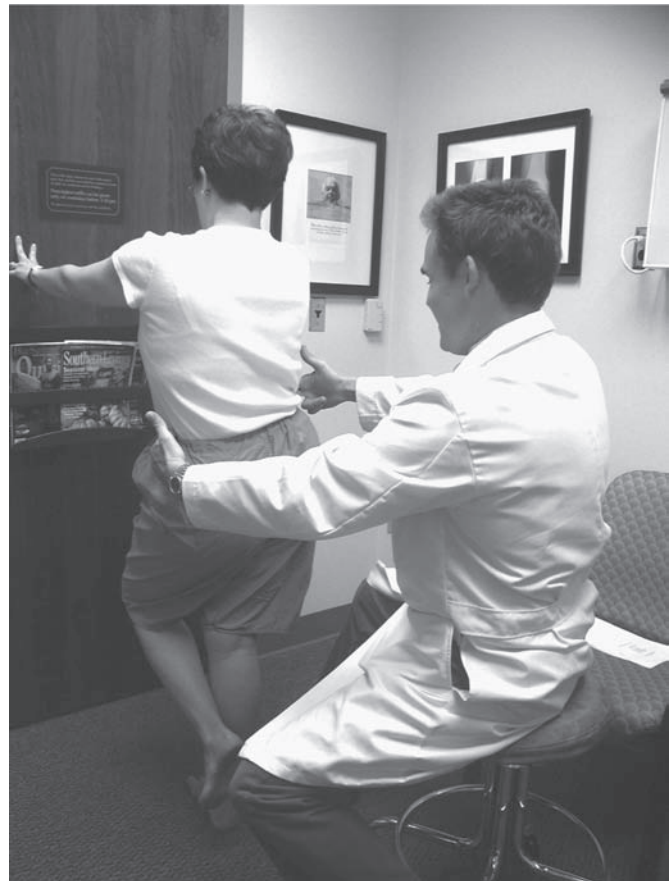

Figure 4.1. Trendelenburg sign is a test of the contralateral leg abductors. The patient lifts the leg and the pelvis is assessed for at least 2 cm of sag. (From Berry D, Steinman *Orthopaedic Surgery Essentials: Adult Reconstruction*. Philadelphia, 2007 with permission.)

[AU3]

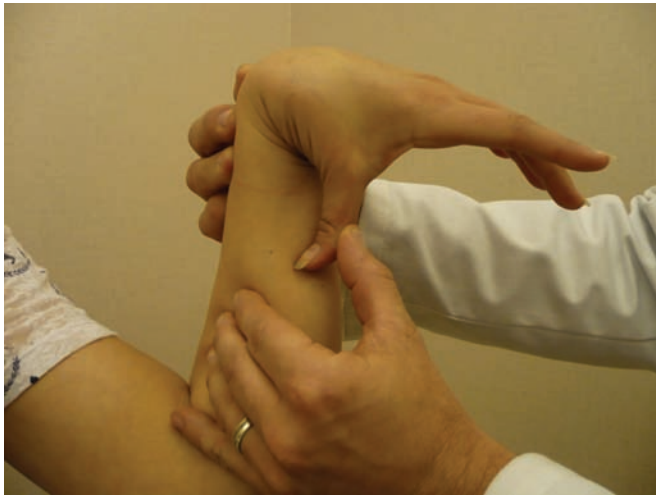

Figure 4.2. The thumb-to-wrist laxity test will determine if the patient has ligament hyperlaxity. A positive test occurs if the patient can touch the anterior forearm with the thumb. [AU4]

The neurological examination will include motor and sensory components with a focus on the L2 through S1 spinal nerves. The motor component will test muscles innervated by the superior gluteal (L4–S1), obturator (L2–4), femoral (L2–4), and sciatic (L4–S3) nerves. To test the superior gluteal nerve (leg abductors), abduct both legs against force. For the obturator nerve (leg

adductors), adduct against resistance. To test the femoral nerve (quadriceps femoris), extend the legs at the knee joint against resistance. Finally, to check the sciatic nerve (hamstrings and lower leg muscles), flex the legs at the knee joint and then dorsiflex, plantar flex, invert, and evert the foot, all against resistance.

Dermatomal sensation should be assessed bilaterally at the upper anterior thigh (L2), mid-anterior thigh (L3), knee (L4), middle three toes (L5), and lateral part of foot (S1) (Fig. 4.3). Special attention should be paid to the anterior thigh, a frequent site of neuralgia caused by compression of the lateral femoral cutaneous nerve as it passes through the pelvis over the psoas muscle and under the inguinal ligament.^{16–19}

Deep tendon reflexes include the patellar and Achilles tendon reflexes. Patellar reflex is assessed by tapping the leg just below the patella at the patellar tendon with leg hanging freely. If the leg extends at the knee, the reflex is present. Ankle reflex, or Achilles reflex, is tested by holding the ankle in dorsiflexion and tapping the calcaneal tendon. If the foot plantar flexes, the reflex is present. [AU5]

The last component of the neurological evaluation is the straight leg raise. The leg is passively raised with the knee held in extension. If the patient feels pain in the lower back or leg, lower the leg 10° and dorsiflex the foot to recreate the radicular pain (Fig. 4.4). A positive test within 0° to 30° indicates a compressed nerve root; a positive test within 30° to 60° suggests sacroiliac disease and greater than 60° suggests a lumbosacral disorder.^{20,21} If the patient leans back at any point during this examination to avoid pain, the test is considered positive.

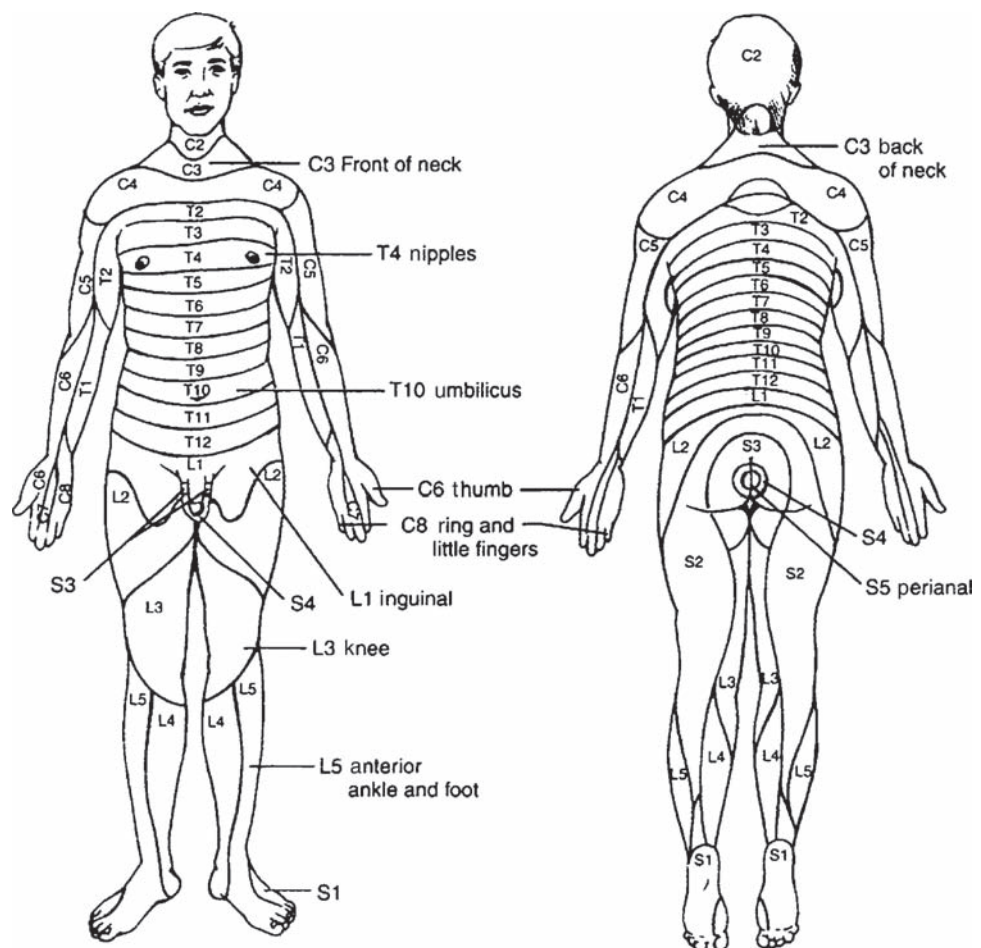
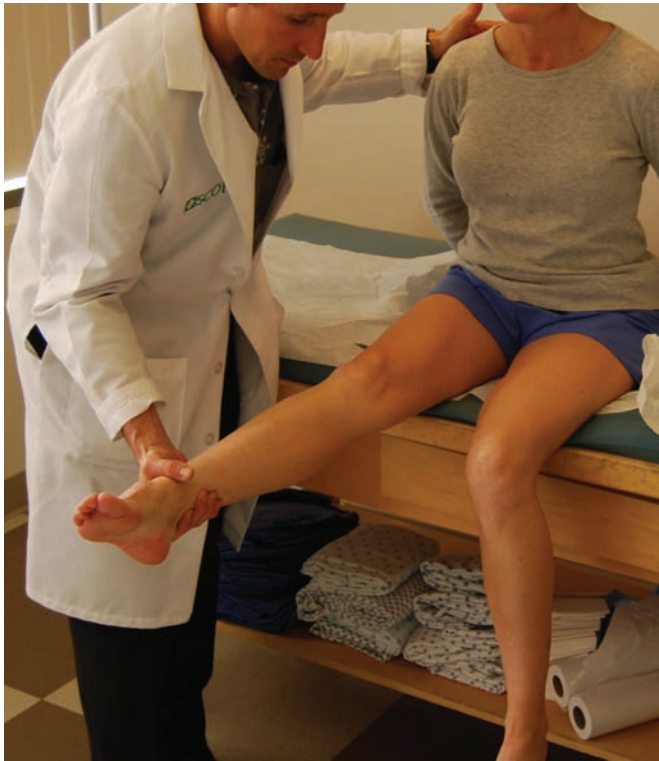

Figure 4.3. The dermatome map shows where to compare sensory function on both legs to assess neurological deficit to the corresponding spinal nerve. (From Berry D, Steinman *Orthopaedic Surgery Essentials: Adult Reconstruction*. Philadelphia, 2007 with permission.)



[AU6] **Figure 4.4.** The straight leg raise test. Raise straight leg until pain is felt (5A), then lower the leg 10° and dorsiflex to recreate the pain (5B).

The final part of the seated examination involves evaluation of internal and external rotation of the hip. Rotation is best evaluated in the seated position because the hip is stabilized at a 90° angle, avoiding variability due to changes in flexion angle.¹⁰ In addition, the seated position stabilizes the pelvis, which is difficult to accomplish in the supine position. The range of internal rotation of the hip is within 20° to 35°, and external rotation is within 30° to 70°. Additionally, the terminally extended hip should internally rotate at least 10°. Loss of internal rotation is one of the initial signals for such problems as arthritis, effusion, and other internal derangements, as well as for slipped capital femoral epiphysis and muscular contractures.²² Excessive internal rotation coupled with diminished external rotation suggests increased femoral anteversion.¹⁴ Significant differences in rotational measurements from one side to another, whether or not in normal range, can indicate FAI or abnormal femoral or acetabular version.¹

SUPINE

The supine examination includes the continued assessment of a range of motion, an abdominal exam, and a trauma assessment followed by provocative testing. To examine flexion, have the patient flex his or her knees and hips toward his or her chest and observe both sides at once. The limit of normal flexion is around 120°; significant loss of flexion can limit the patient's ability to perform activities of daily living.⁷ When evaluating abduction and an adduction range of motion, one should reference the position of the shaft of the femur to the midline of the pelvis. To test abduction, hold the ankle while supporting the leg and manually abduct the leg. Normal abduction is approximately 45°. Adductor contractures can cause a dimin-

ished abduction range of motion. Bringing the leg across the other leg tests adduction. Normal range is 20° to 30°, but may be diminished in the setting of abductor contracture.

Next in the supine examination is the assessment of the abdominal/ilioinguinal area, which begins with the palpation of several landmarks. Palpate the femoral pulse at the femoral triangle. Search for any fascial hernias or other masses in the abdominal region by having the patient contract the rectus abdominus and oblique muscles. Palpate any masses or hernias, if present. Palpate the adductor tubercle (Fig. 4.5A) as the patient adducts the leg; reproduction of pain may indicate adductor tendonitis. Palpate the pubic symphysis (Fig. 4.5A); if there is tenderness, one or more of several issues may be present including fracture, trauma, calcification, or osteitis pubis, and further investigation is required. Pelvic stability is assessed by pushing down on the bilateral iliac crests, looking for independent motion of the hemipelvises. Finally, attempt to elicit the Tinel sign at the femoral nerve by percussing the femoral nerve at the level of the ilioinguinal ligament. A positive Tinel sign occurs with tingling along the femoral nerve, possibly indicating a neurological pathology.

A generalized hip trauma examination includes log roll, heel strike, and the Stinchfield tests. All should cause marked pain in the presence of a hip fracture but may also be painful with intra-articular derangement. Rotating the leg internally and externally in the supine position performs the log roll. Striking the fist against the heel, creating an axial load on the hip, performs the heel strike. With the Stinchfield test, the patient must raise the fully extended leg against the pressure of the examiner's hand upon the thigh. Pressure is gradually increased as the leg is raised. The recreation of hip pain constitutes a positive test and suggests intra-articular or iliopsoas pathology.¹⁴ In the setting of fracture, the patient will normally be unable to perform this test due to pain.

The supine examination concludes with provocative testing. The FADDIR test is performed by bringing the hip into maximal flexion, adduction, and internal rotation (Fig. 4.6). This test may be accentuated by adding an axial load with downward pressure over the knee. Pain in this position constitutes a positive FADDIR test, which may be the most sensitive indicator of FAI. The FADDIR test may also be conducted in the lateral position.

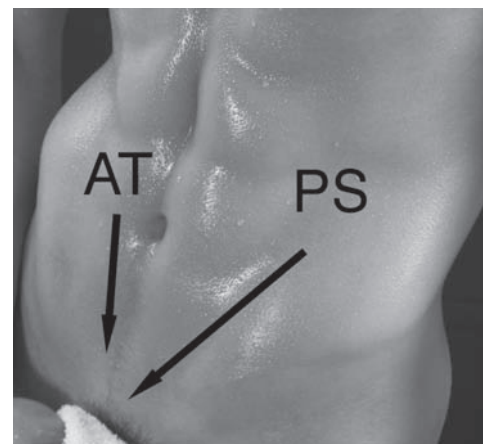


Figure 4.5. Palpation of the adductor tubercle (AT) or the pubic symphysis (PS) can help localize the source of pain. The pubic symphysis is directly in the midline, whereas the adductor tubercle is more lateral on either side of the symphysis.

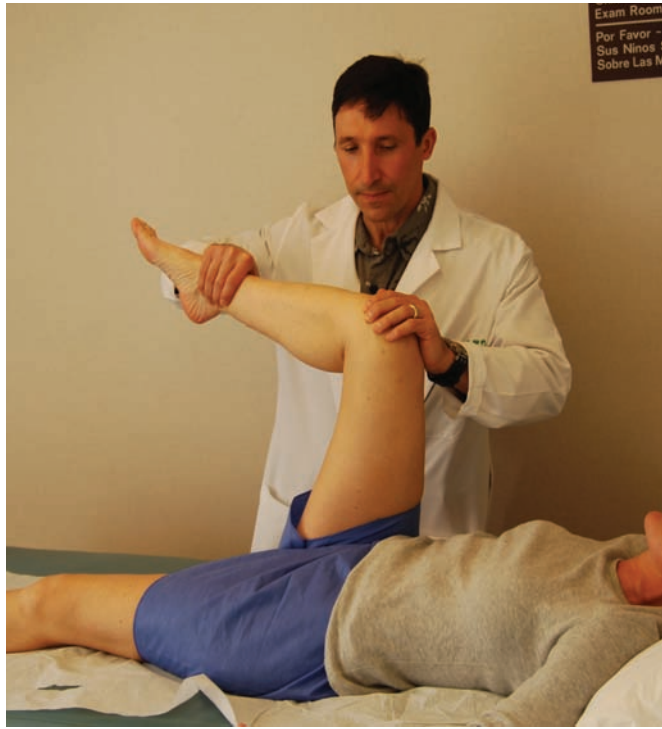

Figure 4.6. Supine FADDIR test. Bring the hip into maximal flexion, adduction, and internal rotation. This can be done in conjunction with an axial load applied at the knee.

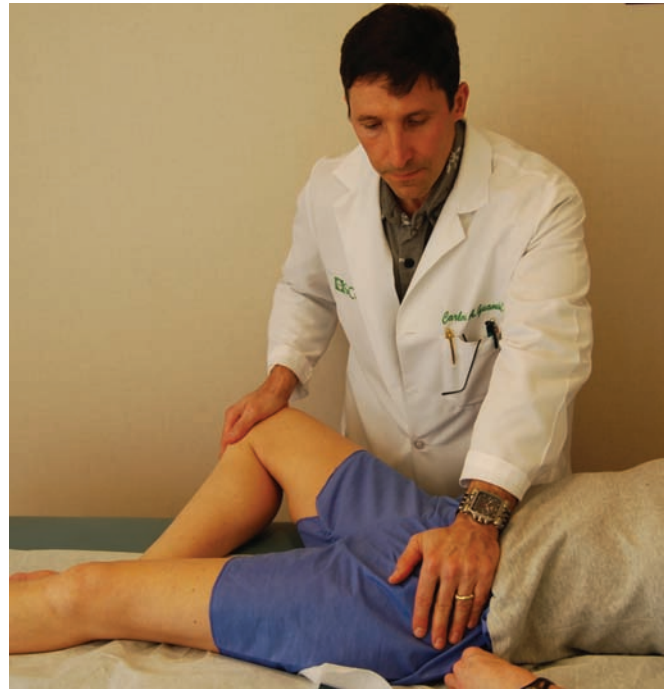

Figure 4.7. The Patrick/FABER test. Have the patient lie in a “figure four” position, with the affected extremity. Press on the affected knee to elicit pain in the sacroiliac region.

To perform the Patrick/FABER test, have the patient lie in a “figure four” position with the affected ankle lying on the thigh of the unaffected leg and then press on the affected knee to cause sacroiliac joint stress (Fig. 4.7). This stress may manifest itself in different types of pain, each delineating a different pathology. Groin pain implicates the iliopsoas as the origin of pain;¹⁴ lateral hip pain suggests lateral FAI; and posterior pain may indicate sacroiliac joint pathology. To assess lateral FAI, move the leg

through the full range of flexion and extension while abducted. Pain during this process signifies lateral rim impingement.

The Thomas test requires pulling the unaffected leg to the chest, flexed at the hip and knee, while lowering the affected leg to the table (Fig. 4.8). The Thomas test is positive if the patient cannot lower the affected thigh all the way to the table and may signify an iliopsoas contracture. A clicking sound during the Thomas test implies a labral tear.¹⁰

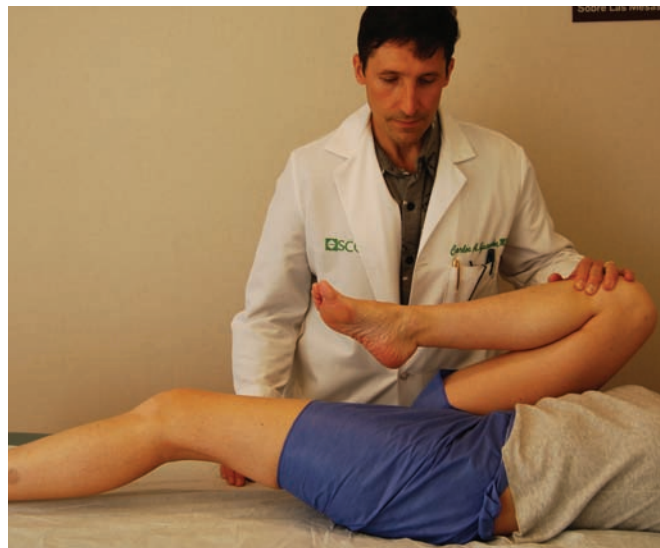
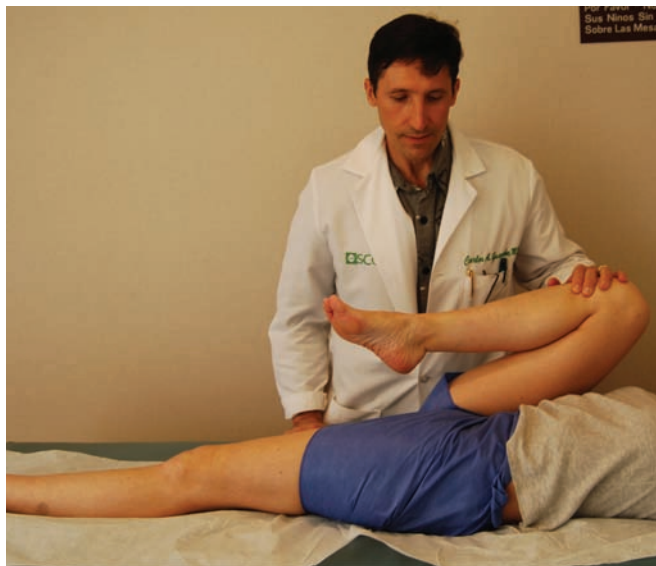
Figure 4.8. The Thomas test. The patient holds the unaffected leg flexed while attempting to lower the affected leg to the table. An inability to lower the affected leg constitutes a positive test, indicating iliopsoas contracture.

The McCarthy test is performed by rolling the hip through full flexion, extension, and internal and external rotation. The goal of this rotation is to emulate the patient's initial pain in order to localize it by finding sites of bony impingement.²³ A positive McCarthy test occurs with reproduction of the original pain and is most common in cases of an acetabular labrum tear.²³⁻²⁶

The final part of the supine exam is the Scour test, which can further delineate whether the hip pain is of an intra-articular or extra-articular nature. First, flex the hip and knee completely so that the knee is pointing to the shoulder. Next, rotate the hip around its arc of motion paying special attention to any bumps, catches, or irregularities during this motion (Fig. 4.9). The presence of any bumps or catches is a positive Scour test and suggests FAI.

LATERAL

The lateral examination takes place with the patient lying on his or her unaffected side. During the lateral examination, palpate several landmarks including the ischial tuberosity, the tensor fascia lata, the IT band, the sciatic nerve, the greater trochanteric bursa, the piriformis, the origin of the gluteus maximus along the ilium, sacrum, coccyx, and the sacroiliac joint (Fig. 4.10). Tenderness in any of these areas implies pathology and should be evaluated more closely. More specifically, tenderness at the ischial tuberosity is associated with biceps femoris contractures, avulsion fracture, or bursitis.¹⁰ Tenderness at the sacroiliac joint would favor a diagnosis of sacroiliac inflammation, which may frequently mimic low back pathology. Pain in

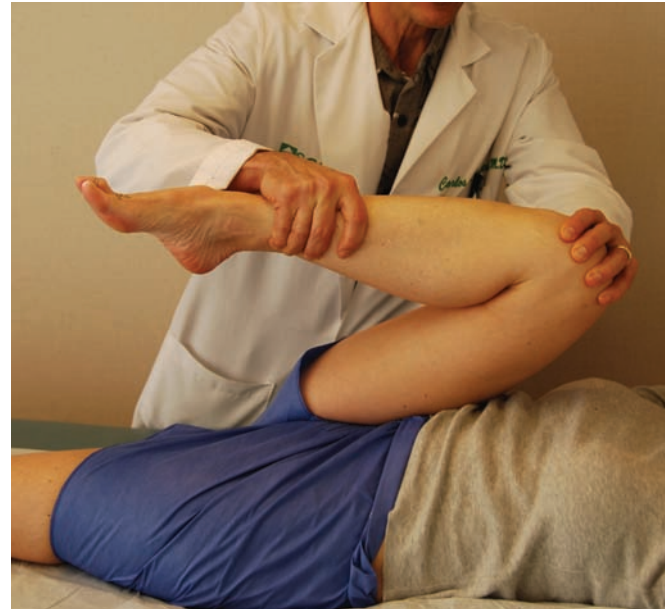
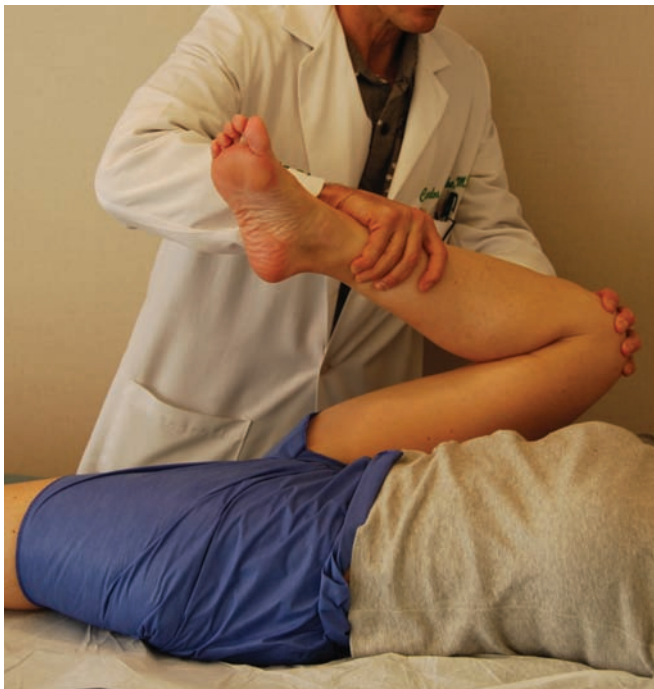
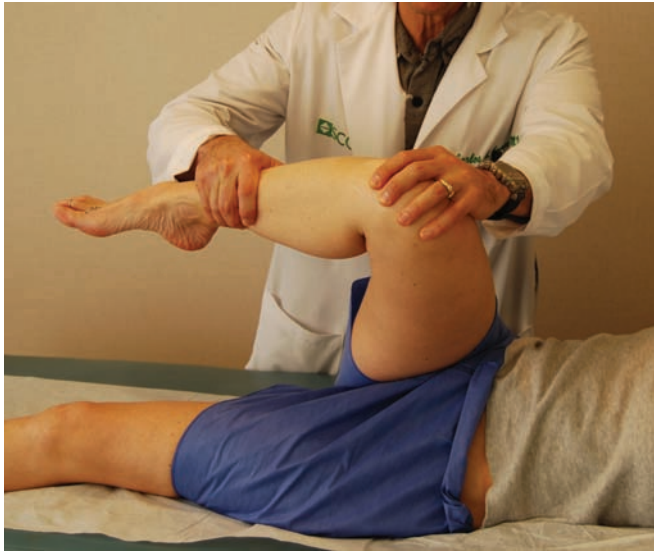Figure 4.9. Scour test. Have the patient flex the leg at the knee and hip and rotate the hip through the full range of motion searching for any irregularities.

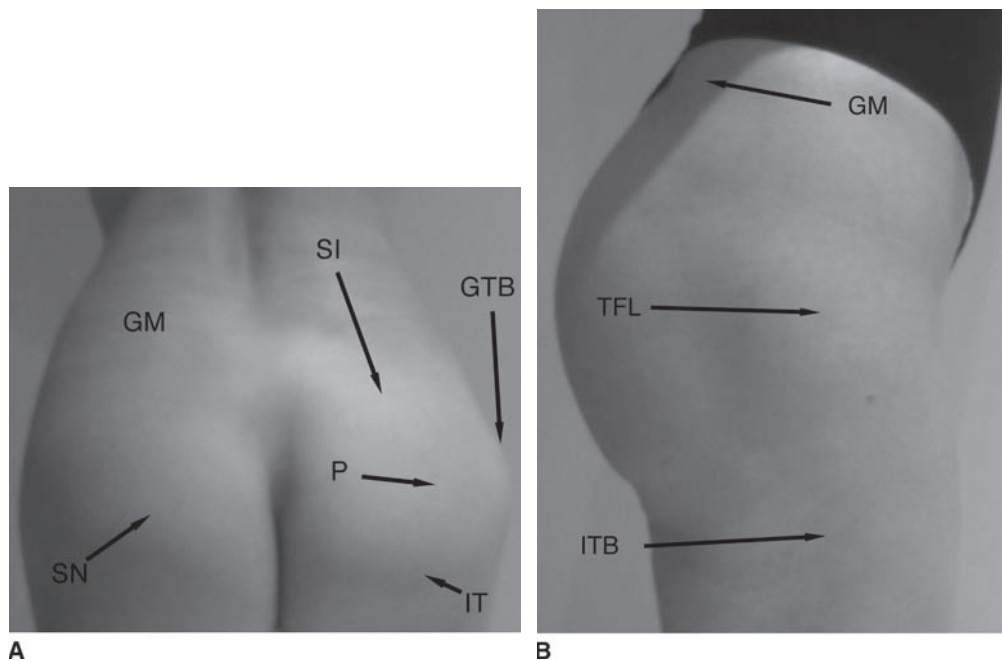


Figure 4.10. A & B: Palpation of several points during the lateral examination is important to localize pain origin. IT, ischial tuberosity; TFL, tensor fascia lata; ITB, iliotibial band; SN, sciatic nerve; TB, greater trochanteric bursa, P, piriformis; GM, gluteus maximus origin; SI, sacroiliac joint.

the greater trochanteric bursa is associated with bursitis or IT band contractures.

The Ober test consists of three parts: extension, neutral, and flexion (Fig. 4.11). To perform the extension test abduct the affected leg and extend it at the hip while flexing the ipsilateral knee. When allowing the leg to fall, note if the leg adducts immediately or if a slight pause or any difficulty in adduction occurs. To perform the neutral test, abduct the leg while the knee is flexed but the hip is in the neutral position, and then allow the leg to fall into adduction. To perform the flexion test rotate the torso to lay both shoulders on the table while both legs are still in the lateral position. Abduct the unaffected leg with the knee fully extended and the hip flexed, and then allow the leg to fall into adduction. In all three tests, the examiner abducts the leg in the specific position and then releases the leg. If the leg maintains its abducted position longer than expected, the Ober test is positive. A positive extension Ober test indicates tensor fascia lata contracture, while a positive neutral test indicates gluteus medius contracture or tear. A positive flexion test indicates gluteus maximus contracture.

To perform the FADDIR test in the lateral position stand behind the patient and place a supporting hand under the patient's knee while using the other hand to palpate the hip (place the index finger on the anterior portion of the hip with the thumb pointing toward the posterior). Have the patient flex, adduct, and internally rotate the leg to elicit pain or discomfort (Fig. 4.12). If any pain or discomfort occurs, the test is thought to be positive.

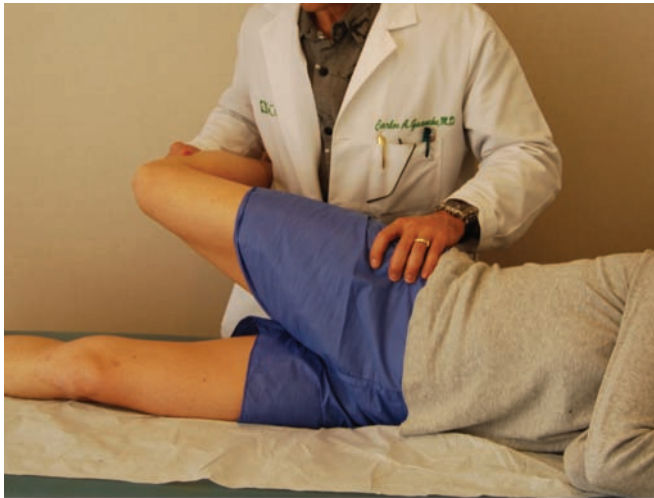The final part of the lateral examination is the abduction–extension–external rotation test (Fig. 4.13). With the knee fully extended, abduct the leg 30° with no rotation, and flex the hip 10°. Externally rotate the leg and place forward pressure on the greater trochanter while bringing the leg from 10° flexion to full extension. If pain occurs with the anterior

pressure and abates in its absence, the test is positive. A positive abduction–extension–external rotation test may indicate anterior acetabular anteversion, iliofemoral ligament strain, or anterior instability of the hip. Patients who are positive for this test should also be assessed for generalized ligamentous laxity.

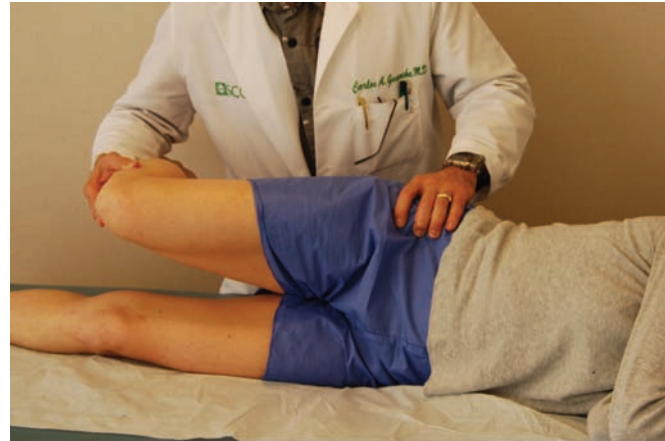PRONE

The final component of the examination takes place in the prone position. Most of the tests and examinations in this position are performed as follow-up to earlier positives. Such examinations include palpation of the sacroiliac region, a modified Thomas test, and the Ely test. If indicated, knee and ankle examination may also be performed in this position. If previous examination has produced sacroiliac pain, palpate the three different areas in the sacroiliac region to specify which area is the origin of pain. These three areas are the suprasacroiliac region, the infrasacroiliac region (near the gluteus maximus), and the lower lumbar vertebral spinous processes (L4–5).

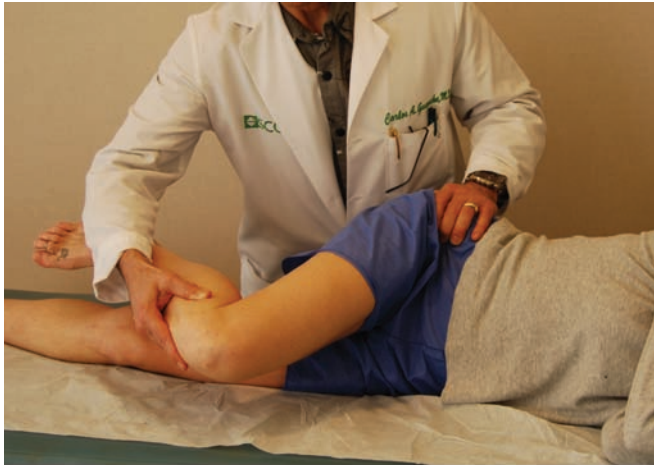The next part of the prone examination will help differentiate between iliopsoas and rectus femoris contractures. The modified Thomas test is used for the former while the Ely test is used to test the latter. To perform the modified Thomas test have the patient lie in the prone position and see if the pelvis rises off the examination table, indicative of an iliopsoas contracture. The Ely test is performed by flexing the leg at the knee until the lower leg is as close to the thigh as possible. If the pelvis and buttocks move upward in this position the test is positive, indicating rectus femoris contracture. Because the rectus femoris crosses both the hip and knee joints, the Ely test would only indicate contractures of that muscle as the bending of the knee stretches the rectus femoris across the knee.



A



B



C

Figure 4.11. The Ober test is performed with the hip extended (A), in a neutral position (B), and flexed (C). The knee is flexed in the extended and neutral test, but extended in the flexed test. Additionally, the patient's shoulders should be on the table during the flexed test.

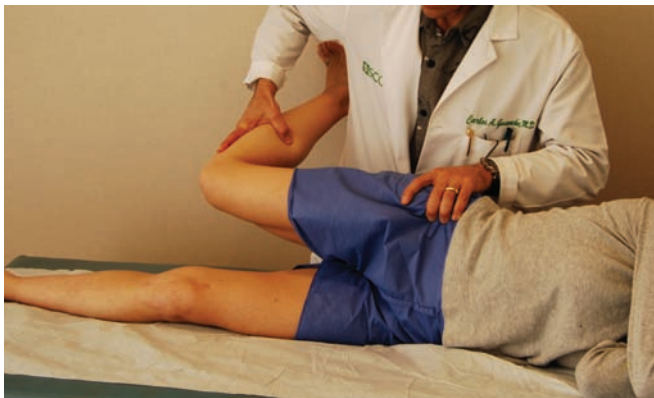

Figure 4.12. Lateral FADDIR test. Flex, adduct, and internally rotate the leg while placing one hand on the knee and the other hand on the hip to test for FAI.

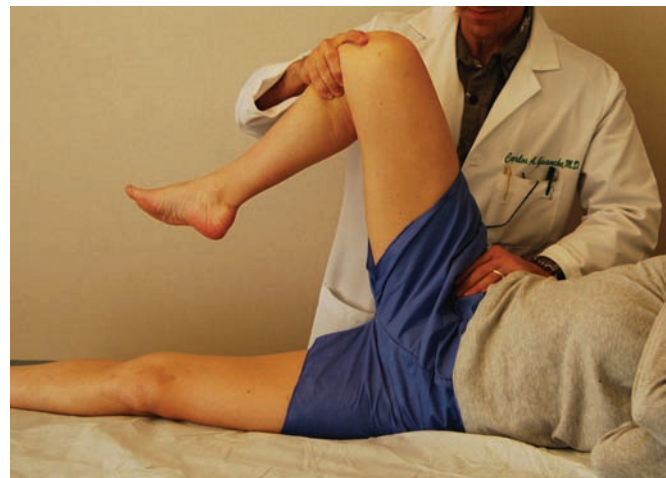

Figure 4.13. Abduction–extension–external rotation test. Extend the knee, abduct the leg 30°, and then externally rotate the leg while placing pressure on the greater trochanter and bringing the leg from 10° flexion to full extension.

CONCLUSION

The examination of the hip can be a confusing and challenging exercise. However, with a systematic approach, the myriad of possible diagnoses can be narrowed down. The conclusions reached through this examination should be used along with the patient's age, lifestyle, aspirations, and physical requirements in making treatment recommendations.

It is also important to keep an open mind regarding the coexistence of pathology that may be concurrent with hip-related pain. Avoiding “tunnel vision” is crucial and concomitant problems must be recognized and addressed along with any hip pathology. If the patient has both hip and back pathology and both are not addressed in the treatment plan, the outcome can be very poor.¹ Furthermore, superfluous radiographic investigation should be avoided. After a good history and physical examination, only 16% of hip complaints necessitate further radiographic study.¹⁰

As with any other physical examination, knowledge of the anatomy of the hip is crucial. The ultimate clarifying factor during the physical examination is a detailed understanding of the anatomy underlying every step. With this understanding, the examiner can unify all parts of the examination and arrive at a clear and correct diagnosis.

REFERENCES

1. Brown MD, Gomez-Martin O, Brookfield KF, et al. Differential diagnosis of hip disease versus spine disease. *Clin Orthop Relat Res*. 2004;419:280–284.
2. Byrd JWT. Hip arthroscopy. Presented at the 2005 Meeting of the Arthroscopic Association of North America. April 8–10, 2005.
3. Longjohn D, Dorr LD. Soft tissue balance of the hip. *J Arthroplasty*. 1998;13(1):97–100.
4. Boyd KT, Peirce NS, Batt ME. Common hip injuries in sports. *Sports Med*. 1997;24:273–288.
5. DeAngelis NA, Busconi BD. Assessment and differential diagnosis of the painful hip. *Clin Orthop Relat Res*. 2003;406:11–18.
6. Domb BG, Drakos M, Starkey C, et al. Injury and illness in the National Basketball Association: A 17-year overview. Submitted to *Am J Sports Med*.
7. Scopp JM, Moorman CT. The assessment of athletic hip injury. *Clin Sports Med*. 2001;20(4):647–659.
8. Braly BA, Beall DP, Martin HD. Clinical examination of the athletic hip. *Clin Sports Med*. 2006;25:199–210.
9. Martin HD. Clinical examination of the hip. *Oper Tech Orthop*. 2005;15:177–181.
10. Margo K, Drezner J, Motzkin D. Evaluation and management of hip pain: An algorithmic approach. *J Fam Pract*. 2003;52(8):607–617.
11. McCarthy J. *Early Hip Disorders: Advances in Detection and Minimally Invasive Treatment*. Boston, MA: Springer; 2003.
12. Magee DJ. Hip. In: Magee DJ, ed. *Orthopedic Physical Assessment*. 3rd ed. Philadelphia, PA: WB Saunders; 1997, p. 460.
13. Hickman JM, Peters CL. Hip pain in the young adult: Diagnosis and treatment of disorders of the acetabular labrum and acetabular dysplasia. *Am J Orthop*. 2001;30:459–467.
14. Reider B, Martel JM. Pelvis, hip and thigh. In: Reider B, Martel JM, eds. *The Orthopedic Physical Examination*. Philadelphia, PA: WB Saunders; 1999, pp. 159–199.
15. Robertson GS, Ristic CD, Bullen BR. The incidence of congenitally absent foot pulses. *Ann R Coll Surg Engl*. 1990;72(2):99–100.
16. Hoppenfeld S, Hutton R. Physical examination of the hip and pelvis. In: Hoppenfeld S, Hutton R, eds. *Physical Examination of the Spine and Extremities*. Upper Saddle River, NJ: Prentice Hall; 1976, pp. 143–169.
17. Jakubowicz M. Topography of the femoral nerve in relation to components of the iliopsoas muscle in human fetuses. *Folia Morphol (Praha)*. 1991;50(1–2):91–101.
18. Ritter JW. Femoral nerve “sheath” for inguinal paravascular lumbar plexus block is not found in human cadavers. *J Clin Anesth*. 1995;7(6):470–473.
19. Robinson DE, Ball KE, Webb PJ. Iliopsoas hematoma with femoral neuropathy presenting a diagnostic dilemma after spinal decompression [case reports]. *Spine*. 2001;26(6):E135–138.
20. Evans RC. *Illustrated Essentials in Orthopedic Physical Assessment*. St. Louis, MO: Mosby; 1994.
21. Hoppenfeld S. *Physical Examination of the Spine and Extremities*. San Mateo, CA: Appleton & Lange; 1976.
22. Troum OM, Cruces JV. The young adult with hip pain: Diagnosis and medical treatment, circa 2004. *Clin Orthop Relat Res*. 2004;418:9–17.
23. McCarthy JC, Noble PC, Schuck M, et al. The role of labral lesions to development of early degenerative hip disease. *Clin Orthop Relat Res*. 2001;393:25–37.
24. Lage LA, Patel JV, Villar RN. The acetabular labral tear: An arthroscopic classification. *Arthroscopy*. 1996;12:269–272.
25. Farjo LA, Glick JM, Sampson TG. Hip arthroscopy for acetabular labral tears. *Arthroscopy*. 1999;15:132–137.
26. Fitzgerald RH, Jr. Acetabular labrum tears: Diagnosis and treatment. *Clin Orthop Relat Res*. 1995;311:60–68.
27. Griffin LY, ed. *Orthopedic Knowledge Update*. Rosemond, IL: Sports Medicine, American Academy of Orthopedic Surgeons; 1994. [AU8]
28. Kujala UM, Kaprio J, Sarna S. Osteoarthritis of weight-bearing joints of lower limbs in former elite male athletes. *BMJ*. 1994;308:230–234.
29. Lindberg H, Roos H, Garsell P. Prevalence of coxarthrosis in former soccer players: 268 players compared with matched controls. *Acta Orthop Scand*. 1993;64:165–167.
30. Marti B, Knobloch M, Tschopp A, et al. Is excessive running predictive of degenerative hip disease?: Controlled study of former elite athletes. *BMJ*. 1989;299:91–93.
31. Vingard E, Alfredsson L, Goldie I, et al. Sports and osteoarthritis of the hip: An epidemiologic study. *Am J Sports Med*. 1993;21:195–200.
32. Spector TD, Harris PA, Hart DJ, et al. Risk of osteoarthritis associated with long-term weight-bearing sports. *Arthritis Rheum*. 1996;39:988–995.
33. Vingard E, Sandmark H, Alfredsson L. Musculoskeletal disorders in former athletes: A cohort study of 114 track and field champions. *Acta Orthop Scand*. 1995;65:289–291.
34. Philippon M. The role of arthroscopic thermal capsulorrhaphy in the hip. *Clin Sports Med*. 2001;20:817.
35. Dorrell JH, Catterall A. The torn acetabular labrum. *J Bone Joint Surg*. 1986;68B:400–403.
36. Has T, Ueo T. Acetabular labral tear: Arthroscopic diagnosis and treatment. *Arthroscopy*. 1999;15:138–141.
37. McCarthy JC, Busconi B. The role of hip arthroscopy in the diagnosis and treatment of hip disease. *Orthopedics*. 1995;18:753–756.
38. Pirouzmand F, Midha R. Subacute femoral compressive neuropathy from iliacus compartment hematoma. *Can J Neurol Sci*. 2001;28:155–158.
39. Salminen JJ, Oksanen A, Maki P, et al. Leisure time physical activity in the young: Correlation with low-back pain, spinal mobility and trunk muscle strength in 15-year-old school children. *Int J Sports Med*. 1993;14:406–410.

Author Queries:

[AU1] Should the words “will be discussed during the seated examination” be rephrased as “this is discussed in the section “Sitting”?”

[AU2] Please specify the section or the chapter.

[AU3] Please provide complete reference details in the source line of Figures 4.1 & 4.3.

[AU4] Please provide source line for Figures 4.2, 4.4 to 4.13.

[AU5] Is the insertion of “or Achilles reflex” in the sentence beginning “Ankle reflex...” OK?

[AU6] 5A, 5B are not indicated in the artwork of Figure 4.4. Please check.

[AU7] Please update the reference.

[AU8] References 27 to 39 are not cited in the text. Please check.