

# Clinical Examination of the Hip Joint in Athletes

**Benjamin G. Domb, Adam G. Brooks, and J. W. Byrd**

In recent years, a quantum leap has been made in the diagnosis and treatment of nonarthritic hip injuries. This evolution can be attributed in part to better imaging, improved understanding of the anatomy and biomechanics of the hip, and progress in surgical technology and techniques. Among other advances, labral tears and early cartilage damage have been identified as common sources of pain. Furthermore, important etiologies for hip injury have been explained, including femoroacetabular impingement (FAI).<sup>1</sup> These advances have led to a rapid increase in the correct diagnosis of nonarthritic hip pain.

Concurrent with the advances in diagnosis, a revolution in surgical treatment of hip injuries is emerging. Many joint-preserving surgeries including labral debridement or repair and decompression of impinging bone lesions can now be performed arthroscopically. These arthroscopic hip surgeries have provided new options with high clinical success rates for patients with nonarthritic hip pain.<sup>2</sup>

The nonarthritic hip poses a diagnostic dilemma because pain is difficult to localize for both the patient and the clinician. As many as 60% of patients requiring hip arthroscopy are initially misdiagnosed, and in one study these patients remained misdiagnosed for an average of 7 months.<sup>3</sup> With the new body of knowledge involving nonarthritic hip injuries, clinicians have a tremendous opportunity to help such patients arrive at a diagnosis and be successfully treated. A thorough history and physical are extremely important in determining hip pathology, which is exceptionally relevant given current innovations in therapy for hip pathology. Although the hip is frequently overlooked as the original source of pain or pathology, one study demonstrated that clinical assessment can be 98% reliable in detecting the presence of a hip-joint problem.<sup>4</sup> Examination of the hip region can be complex, however, because of coexistent pathology, secondary dysfunction, or coincidental findings. For example, hip-joint disease might coexist with lumbar-spine disease. Disorders of the paravertebral muscles can cause soft-tissue instability and irregular tension on the hip,<sup>5</sup> and contractures of the iliopsoas and hamstrings can cause back pain.<sup>6</sup> In addition, hip pathology might coexist with athletic pubalgia, especially in male athletes. Symptoms of athletic pubalgia require a systematic and reproducible physical examination of the hip with appropriate

---

Domb is with Loyola University Chicago. Brooks is with the Keck School of Medicine, University of Southern California. Byrd is with the Nashville Sports Medicine and Orthopaedic Center, Dept of Orthopaedics and Rehabilitation.

imaging and diagnostic tests to distinguish pubalgia from intra-articular hip pathology.

Hip-joint disorders often remain undetected for protracted periods of time. In the course of compensating for their symptoms, patients often develop secondary dysfunction. This chronic pathology can lead to symptoms of trochanteric bursitis or chronic gluteal discomfort. The examination findings for the secondary disorders might be more evident and mask the underlying problem with the hip. In addition, there might also be coincidental findings unrelated to disorders of the hip. Snapping of the iliopsoas tendon and iliotibial band is usually an incidental finding without clinical significance, but this snapping can become a source of symptoms or might exist coincidentally with hip-joint pathology.

Myriad structures can create similar or overlapping symptoms. In addition to the joint, the clinician must be cognizant of bone problems, surrounding musculotendinous and bursal structures, circulatory pathology, neurological disorders including numerous small sensory nerves, and even visceral disorders that can refer symptoms to the hip area. To separate these problems this article will detail appropriate evaluation of the hip by history and physical exam, which will consist of inspection, measurements, symptom localization, and muscle-strength and special tests.

## History

A detailed history of the hip should include the patient's age, the chief complaint, and the presence or absence of trauma, as well as any treatments the patient has already used, such as nonsteroidal anti-inflammatory drugs, physical therapy, or assistive devices.<sup>7</sup> In addition, a past medical history of hip disorders or dislocations during birth or infancy, past surgeries, or major illnesses should be noted along with a family history of hip dislocations or disorders, degenerative joint disease, rheumatological disorders, or cancer.

Because various disorders can manifest as hip pain, the history might be equally varied with regard to onset, duration, and severity of symptoms. Acute labral tears associated with an injury often remain undiagnosed for decades and can present as chronic disorders, and patients with a degenerative labral tear might describe the acute onset of symptoms associated with a relatively innocuous episode and gradual progression of symptoms. Because back and hip pain often coexist, care should be taken to note the relative severity of each type of pain. In addition, weakness, numbness, or paresthesia in the lower extremity suggests neural compression, which often occurs in the lumbar spine.

In general, a positive history of significant trauma is a good prognostic indicator of a potentially correctable problem.<sup>2</sup> Insidious onset of symptoms is a poorer prognostic indicator and suggests either underlying degenerative disease or some predisposition to injury. Patients might recount a minor precipitating episode such as a twisting injury, but even under such circumstances, there might be an underlying susceptibility to joint damage with a less certain prognosis. With any hip-joint problem, the clinician must look closely for predisposing factors. For example, FAI is a recognized cause of joint breakdown in young adults.<sup>8</sup> Mechanical symptoms such as locking, catching, popping, or sharp stabbing pain are also better prognostic indicators of a correctable problem, whereas pain in the

absence of mechanical symptoms is a poorer predictor.<sup>9</sup> The presence of a “pop” or “click” during examination of the hip is an ambiguous finding at best, however, one that is often not proportionally related to the hip pathology. Although these sounds might suggest an unstable lesion inside the joint, many painful intra-articular problems never demonstrate this finding, and popping and clicking can occur from extra-articular causes, most of which are normal.

There are characteristic features of the history that often suggest a mechanical hip problem:

- Symptoms worse with activities
- Twisting, such as turning, changing directions
- Seated position might be uncomfortable, especially with hip flexion
- Rising from seated position often painful (catching)
- Difficulty ascending and descending stairs
- Symptoms with entering and exiting an automobile
- Dyspareunia (painful sexual intercourse)
- Difficulty with shoes, socks, hose, and so on<sup>10</sup>

These characteristics are helpful in localizing the hip as the source of trouble but are not specific for the type of pathology. Pain is usually worse with activities with a mechanical problem. Straight-plane activities such as straight-ahead walking or even running are often well tolerated, whereas twisting maneuvers such as simply turning to change direction might produce sharp pain, especially turning toward the symptomatic side, which places the hip in internal rotation. Sitting for prolonged periods might be uncomfortable, especially if the hip is placed in excessive flexion. Rising from the seated position might be especially painful and the patient might experience an accompanying catch or sharp stabbing sensation. Symptoms are worse with ascending or descending stairs or other inclines. Entering and exiting an automobile are often difficult with accompanying pain because the hip is loaded in a flexed position along with twisting maneuvers. Dyspareunia is often an issue because of hip-joint pain. This is more commonly a problem for women but can be a difficulty for men, as well. Difficulty with shoes, socks, or hose might simply be caused by pain or might reflect restricted rotational motion and more advanced hip-joint involvement.

Finally and most important, the examiner should be sure to note any “red flags” during the history, such as fever, malaise, night sweats, weight loss, night pain, intravenous drug use, cancer history, or known immunocompromised state, which can indicate systemic problems that necessitate further diagnostic testing.<sup>11</sup> Based on the information obtained in the history, a preliminary differential diagnosis should be formulated. The history helps the examiner perform an appropriately directed physical examination.

## Physical Examination

Although the information obtained in the history is a screening tool and helps direct the examination, it should not unduly prejudice the approach. The examiner must be systematic and thorough to avoid potential pitfalls and missed diagnoses.

In reference to examination of the hip, the famous orthopedic surgeon Otto Aufranc noted that “more is missed by not looking than by not knowing.”<sup>12</sup>

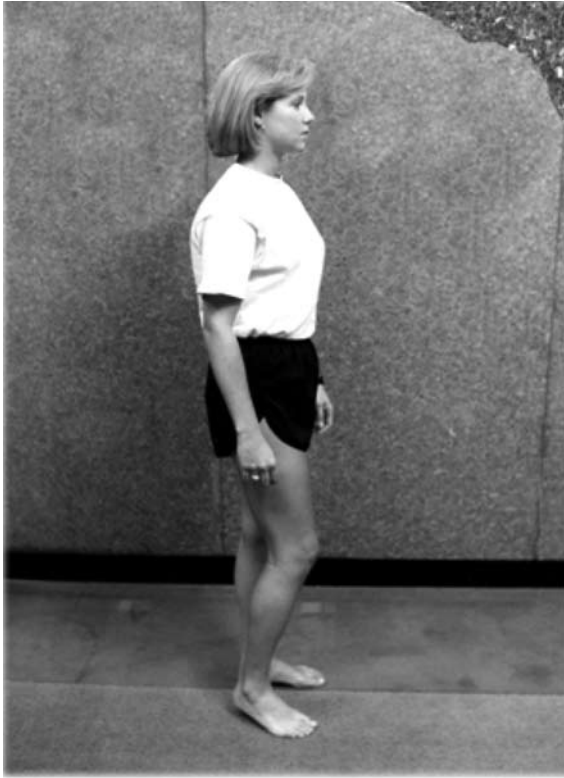## Inspection

The most important aspects of inspection are stance and gait. The patient’s posture is observed in both the standing and the seated position. Any splinting or protective maneuvers used to alleviate stresses on the hip joint are noted. In the standing position, the examiner might appreciate a slightly flexed position of the involved hip and concomitantly the ipsilateral knee (Figure 1). In the seated position, slouching or listing to the uninvolved side avoids extremes of flexion (Figure 2).

Gait should be observed for 6 to 8 full strides from both the frontal and sagittal planes, with close attention paid to stride length, internal or external rotation of the foot, pelvic rotation, and stance phase.<sup>13</sup> An antalgic gait, one during which the patient limps to minimize the stance phase on the painful side while accentuating flexion to avoid painful extension, is often present, depending on the severity of symptoms. Varying degrees of abductor lurch (also known as Trendelenburg gait) might also be present as the patient attempts to place the center of gravity over the hip, reducing the forces on the joint. Excessive internal or external rotation of the hip should be noted during walking for later assessment. Finally, a short-leg limp during gait might imply either iliotibial-band pathology or true or false leg-length discrepancies. Observation is made for any asymmetry, gross atrophy, spinal alignment, or pelvic obliquity that might be fixed or associated with a gross leg-length discrepancy.

Observation is also made for the presence of any clinical popping, snapping, or clicking as described in the subjective examination. The examiner should also observe whether the patient can reproduce such noises. Snapping of the iliopsoas tendon is a common incidental finding, often without clinical significance. The snapping can become painful, however, and might be difficult to distinguish from an intra-articular problem. Although snapping is sometimes subtle and better detected by the patient than the examiner, it is often quite prominent with a distinct audible component. The maneuver to elicit this snapping will be discussed later, but often the patient can better demonstrate this dynamic process. The maneuver performed by the patient can occur while sitting, standing, or lying down, but regardless of position, the snapping usually occurs when going from flexion to extension. It is important not to misinterpret snapping of the iliopsoas tendon as an intra-articular problem, but it is also likely that numerous intra-articular disorders are misdiagnosed as a “snapping hip syndrome.” For recalcitrant symptomatic snapping of the iliopsoas tendon, fluoroscopy with iliopsoas bursography and ultrasonography can often substantiate the source. These studies might not be conclusive, however, and the history and examination findings remain the most reliable clinical assessment tool.

Snapping of the iliotibial band is more easily distinguished from a hip-joint disorder because of its lateral location.<sup>14</sup> These patients frequently present with a sensation that their hip is subluxing or dislocating. They can often demonstrate this dynamic process voluntarily. The visual appearance is created by the tensor fascia lata’s flipping back and forth across the greater trochanter, not by instability of the hip. A good generalization regarding snapping-hip syndromes is that a



**Figure 1** — During stance, a patient with an irritated hip will tend to stand with the joint slightly flexed. Consequently, the knee will be slightly flexed, as well. This combined position of slight flexion creates an effective leg-length discrepancy. To avoid dropping the pelvis on the affected side, the patient will tend to rise slightly on his or her toes. (Reprinted from Byrd.<sup>10</sup>)

snapping iliopsoas tendon can be heard from across the room, and a snapping iliotibial band can be seen from across the room.

## Measurements and Range of Motion

Certain measurements should be recorded as a routine part of the assessment. Differences in the height of a shoulder relative to the ipsilateral iliac crest or the distance from the anterior superior iliac spine to the ipsilateral medial malleolus suggest a true leg-length discrepancy (Figure 3). Significant leg-length discrepancies (<1.5 cm) might be associated with a variety of chronic conditions. Typically, if leg-length difference appears to be a contributing factor, the provider should try to correct for half of the recorded discrepancy in the course of conservative treatment, preferably with an insert that is cosmetically more acceptable than a built-up shoe.

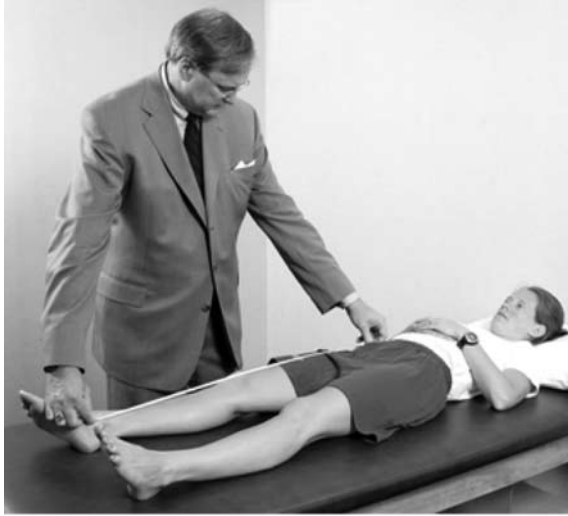

**Figure 2** — In the seated position, slouching and listing to the uninvolved side allows the hip to seek a slightly less flexed position. This is usually combined with slight abduction and external rotation, which relaxes the capsule. (Reprinted from Byrd.<sup>10</sup>)

Thigh circumference, although a crude measurement, might reflect chronic conditions and muscle atrophy (Figure 4). Measuring the uninvolved side to compare with the involved side is crucial. Sequential measurement on subsequent examination might be a helpful indicator of response to therapy. Thigh circumference only indirectly reflects hip function, because hip disease usually affects the entire lower extremity.

Laxity can be assessed by checking for hyperextension of the knee and elbow, along with the thumb-to-wrist exam. The thumb-to-wrist exam involves an attempt by the patient to touch the anterior forearm with the thumb. A positive thumb-to-wrist exam along with hyperextension of the knee and elbow beyond  $5^{\circ}$  are suggestive of generalized hyperlaxity of the ligaments.<sup>15</sup> Capsular laxity of the hip can be diagnosed using the Dial test.<sup>16</sup> In the supine position the examiner places his or her hands on the femur and the tibia while internally rotating the lower leg. After release of the lower leg, any subsequent external rotation beyond  $45^{\circ}$  constitutes a positive Dial test.

It is important to accurately record hip range of motion (ROM) in a consistent and reproducible fashion. Although reduced ROM itself is rarely an indication for arthroscopic intervention, it is often a good indicator of the extent of disease and

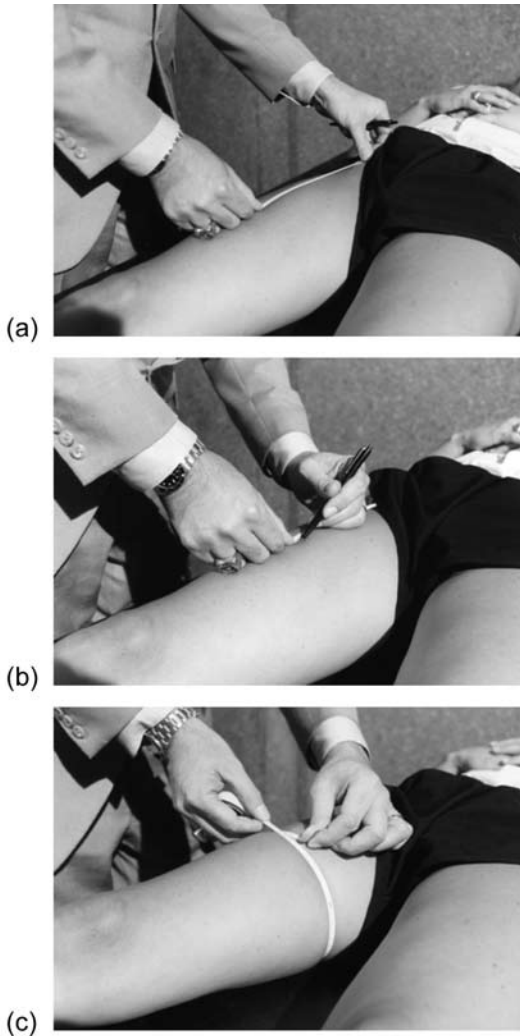


**Figure 3** — Leg lengths are measured from the anterior superior iliac spine to the medial malleolus. (Reprinted from Byrd.<sup>10</sup>)

response to treatment. The degree of flexion and the presence of a flexion contracture are determined by using the Thomas test; in the supine position the patient pulls the unaffected leg to the chest in flexion at the knee and hip while lowering the affected leg to the table. The modified Thomas test can be performed in the prone position with both legs extended at the hip. If the patient's pelvis rises off of the table, an iliopsoas contracture might be present. Maximal extension of the uninvolved hip in the supine position stabilizes the pelvis, eliminating the contribution of pelvic tilt in recording flexion of the involved hip; the normal range of flexion is up to  $120^{\circ}$ .<sup>17</sup> Conversely, maximal flexion of the uninvolved hip in the supine position locks the pelvis and allows assessment for a flexion contracture of the involved hip. Significant loss of flexion or extension can limit the performance of activities of daily living.<sup>7</sup>

To assess internal and external rotation, have the patient sit to stabilize the hip at  $90^{\circ}$  of flexion. The seated position will stabilize the pelvis and the flexion angle.<sup>18</sup> The normal range for internal rotation of the hip is  $40^{\circ}$  to  $45^{\circ}$ , and the normal range for external rotation is  $45^{\circ}$  to  $50^{\circ}$ .<sup>17</sup> Loss of internal rotation suggests arthritis, effusion, a slipped capital femoral epiphysis, or muscle contractures.<sup>19,20</sup> Excessive internal rotation with decreased external rotation suggests increased femoral anteversion.<sup>20</sup> Significant side-to-side differences in rotational measurements, whether or not in the normal range, can suggest hip pathology such as FAI or abnormal femoral or acetabular version.<sup>6</sup>

When evaluating abduction and adduction ROM, one should reference the position of the shaft of the femur to the midline of the pelvis. To test abduction, hold the ankle while supporting the leg and manually abduct the leg. Normal abduction is approximately  $45^{\circ}$ .<sup>17</sup> Adductor contractures can cause diminished abduction ROM. Pathology of the abductor muscles can be assessed using the



**Figure 4** — Thigh circumference should be measured at a fixed position, both for consistency of measurement of the affected and unaffected limbs and for consistency of measurement on subsequent examinations. (a) A tape measure is placed from the anterior superior iliac spine toward the center of the patella. (b) A selected distance below the anterior superior iliac spine is marked (typically 18 cm). (c) Thigh circumference is then recorded at this fixed position. (Reprinted from Byrd.<sup>10</sup>)

Trendelenburg test, during which the patient lifts the contralateral leg off the floor while standing. Pelvic sag of greater than 2 cm demonstrates incompetence of abductor function (Figure 5). To establish a baseline, the uninvolved side should be examined first. Finally, bringing one leg across the other leg tests adduction.



The normal range of adduction is  $20^{\circ}$  to  $30^{\circ}$ ; this might be diminished in the setting of abductor contracture.<sup>17</sup>

## Symptom Localization

**The 1-Finger Rule.** Although less well applied to the hip than to other joints such as the knee, asking the patient to use 1 finger to point to the painful location is still an important part of the physical exam. This question provides much useful information before palpation by allowing the examiner to discern the point of maximal tenderness. Consequently, this area is reserved until last when performing the examination. This knowledge forces the examiner to be more systematic, exploring uninvolved areas first, and enhances the patient's trust by not stimulating pain at the beginning of the examination.



**Figure 5** — The patient stands on the affected right leg, lifting the left leg off the ground. With normal abductor strength, the pelvis should remain level. As illustrated here, however, with abductor weakness the pelvis drops toward to contralateral side, reflecting a positive Trendelenburg test. (Reprinted from Byrd.<sup>10</sup>)

Hilton's law states,

The same trunks of nerves whose branches supply the groups of muscles moving a joint furnish also a distribution of nerves to the skin over the insertion of the same muscles, and the interior of the joint receives its nerves from the same source.<sup>21(p591)</sup>

Although this relationship might ensure physiological harmony among the various structures, it also explains why muscle spasms and cutaneous sensations might accompany joint irritation.

Classic mechanical hip pain is described as being anterior, typically emanating from the groin area. The hip joint receives innervation from the branches of L2 to S1 of the lumbosacral plexus (predominantly L3). Consequently, hip symptoms might be referred to the L3 dermatome, which explains the presence of symptoms referred to the anterior and medial thigh, distally to the level of the knee. A common compression of the lateral femoral cutaneous nerve as it passes through the pelvis over the psoas muscle and under the inguinal ligament might present as neuralgia in the L2 or L3 dermatome.<sup>22–25</sup> Intracapsular hip pathology almost always has a component of anterior hip pain. There might also be a sensation of deep, lateral discomfort or posterior pain, but usually only in conjunction with a predominant anterior component.

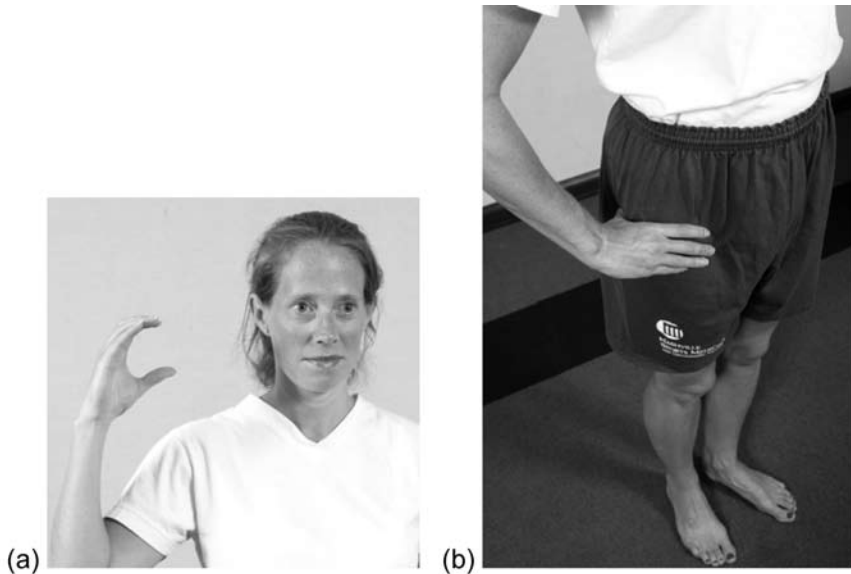
**The C Sign.** The classic complaint of patients with hip pathology is “groin pain.” One author (JWB), however, has identified a common characteristic sign of patients presenting with hip disorders. They cup their hand above the greater trochanter when describing deep interior hip pain. The hand forms a C, and thus this has been termed the C-sign (Figure 6).<sup>10</sup> Because of the position of the hand, this can be misinterpreted as indicating lateral pathology such as at the iliotibial band or trochanteric bursitis, but quite characteristically, the patient is describing deep interior hip pain.

**Palpation.** Palpation is usually unrevealing as far as any specific areas of discomfort related to an intra-articular source of hip symptoms. Obviously, one must be familiar with the topographical and deep anatomy to correlate the structures being palpated. Aufranc noted that “a continuing study of anatomy marks the difference between good and expert ability.”<sup>12</sup>

Palpation is used in part to assess potential sources of pain other than the joint itself. It is important to be systematic, palpating the lumbar spine, sacroiliac joints, ischium, iliac crest, lateral aspect of the greater trochanter and trochanteric bursa, muscle bellies, and even the pubic symphysis, each of which might elicit information regarding a potential source of hip symptoms. The femoral nerve should also be palpated at the level of the ilioinguinal ligament to attempt to elicit Tinel's sign, which would suggest a neurological pathology.

While in the sitting position the patient's circulation must also be assessed by palpation of the dorsalis pedis and posterior tibial pulses along with an inspection of the skin and lymphatics around the hip. Both sides should be compared for pulse strength and lymphadenopathy.

**Muscle Strength.** Manual muscle testing is a crude measure of hip function but can elicit useful information. If injury to a specific muscle group is suspected,



**Figure 6** — The C sign. This term reflects (a) the shape of the hand when a patient describes deep interior hip pain. (b) The hand is cupped above the greater trochanter with the thumb posterior and the fingers gripping deep into the anterior groin. (Reprinted from Byrd.<sup>10</sup>)

resisted contraction should reproduce localized symptoms. The following muscle groups should be tested: leg abductors (superior gluteal nerve; L4–S1), leg adductors (obturator; L2–L4), knee extensors and hip flexors (femoral; L2–L4), hip extensors (inferior gluteal nerve; L5–S2), and knee flexors and lower leg muscles (sciatic; L4–S3).

Active ROM and resisted active ROM might also reproduce joint symptoms. With careful interpretation, however, a distinction can be made between symptoms of a muscle strain and hip pain. This differentiation might be least clear with a strain of the hip flexors. In this setting, active hip flexion reproduces pain, whereas passive flexion should not.

## Special Tests

Special tests include maneuvers used to define other sources of symptoms, as well as those used to define symptoms localized to the hip. The examiner should also be aware of how tests for other sources might affect a painful hip. The following special tests will be divided into tests completed in the sitting, supine, lateral, and prone positions.

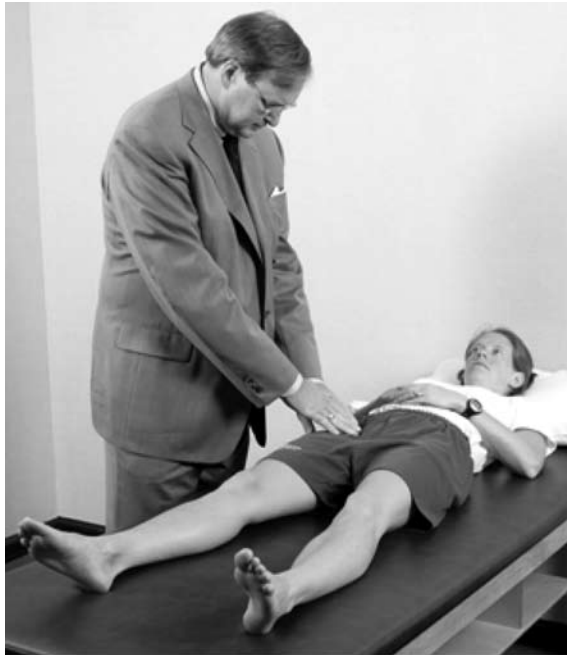**Supine.** Athletic pubalgia occurs most often in male athletes.<sup>26</sup> The symptoms emanate from the groin, and the findings can be confused with a hip-joint problem. This condition often coexists with hip-joint pathology in athletes. Diminished rotational motion of the hip is compensated for by increased pelvic motion,

which places more stress on the pelvic stabilizers and can result in soft-tissue breakdown of the lower abdominal muscles, pelvic floor, and adductor origins. This breakdown is characterized by localized soft-tissue tenderness to palpation on examination (Figure 7) and the absence of discomfort with passive ROM that would be observed in patients with hip-joint pathology. Resisted sit-ups, hip adduction, and occasionally hip flexion might also precipitate symptoms associated with this soft-tissue disorder.

The straight-leg raise (SLR) is important for assessing signs related to irritation of the lumbar nerve root (Figure 8). It might also provoke local joint symptoms. To perform this test the leg is passively raised with the knee held in extension. If the patient feels pain in the lower back or leg, lower the leg  $10^\circ$  and dorsiflex the foot to recreate the radicular pain; pain is considered a positive test. A positive test within  $0^\circ$  to  $30^\circ$  suggests a compressed nerve root, a positive test within  $30^\circ$  to  $60^\circ$  suggests sacroiliac disease, and a positive test greater than  $60^\circ$  suggests a lumbosacral disorder.<sup>27,28</sup>

An active SLR or SLR against resistance often elicits hip symptoms (Figure 9). In this test the patient must flex the leg at the hip against resistance in the supine position. This maneuver generates a force of several times body weight across the articular surfaces and can actually generate more force than walking.

The most specific test for hip pain is “log rolling” the hip back and forth (Figure 10). This test involves moving only the femoral head in relation to the



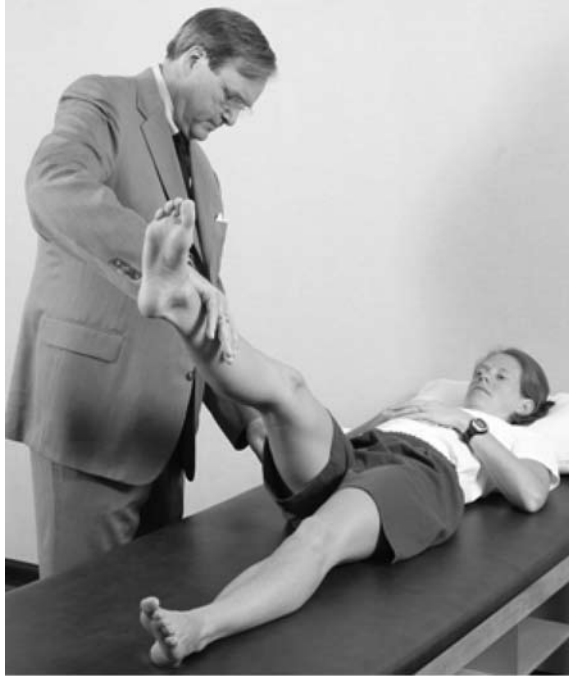**Figure 7** — Tenderness to palpation reflects an extra-articular process that, among athletes, commonly includes athletic pubalgia. (Reprinted from Byrd.<sup>10</sup>)



**Figure 8** — The classic straight-leg-raise test is performed to assess tension signs of lumbar-nerve-root irritation. A positive interpretation is characterized by reproduction of radiating pain along a dermatomal distribution of the lower extremity. It might also recreate local joint symptoms or discomfort in stretching the hamstring tendons. (Reprinted from Byrd.<sup>10</sup>)

acetabulum and the surrounding capsule. The leg should be rotated internally and then externally while the patient is supine. No significant excursion or stress should be placed on myotendinous structures or nerves. Absence of a positive log-roll test does not preclude the hip as a source of symptoms, but its presence greatly raises the suspicion. Additional tests that complement the log roll include the heel strike and the Stinchfield test. Heel strike consists of striking the fist against the heel, creating an axial load on the hip. With the Stinchfield test, the patient must raise the fully extended leg against the pressure of the examiner's hand on the thigh. Pressure is gradually increased as the leg is raised. The recreation of hip pain constitutes a positive test and suggests intra-articular or iliopsoas pathology.<sup>20</sup> In the setting of a fracture, the patient will normally be unable to perform this test because of pain.

Forced flexion combined with internal rotation and adduction is a more sensitive maneuver, which might elicit symptoms associated with even subtle hip pathology (Figure 11). This is often referred to as an “impingement test,” eliciting symptoms associated with FAI. This maneuver is usually uncomfortable with any irritable hip, however, and is not specific for the nature of the pathology. An accompanying pop or click might be present, but it is more important to determine



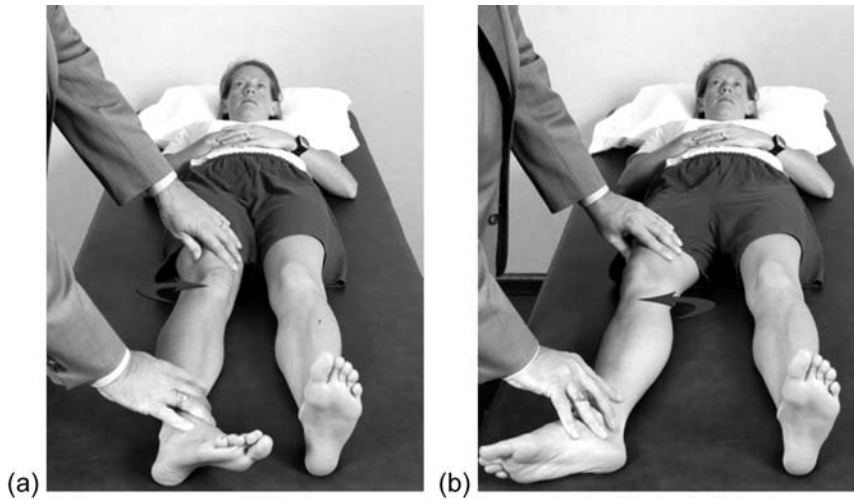**Figure 9** — An active straight-leg raise, or especially a leg raise against resistance, generates compressive forces of many times body weight across the hip joint. Consequently, this is often painful, especially when there is even a mild degree of underlying degenerative disease. (Reprinted from Byrd.<sup>10</sup>)

whether this maneuver reproduces the type of hip pain that the patient experiences with activities. This maneuver might normally be uncomfortable, so it is important to compare the response on the symptomatic and asymptomatic sides. Alternatively, forced abduction with external rotation will sometimes produce symptoms (Figure 12).

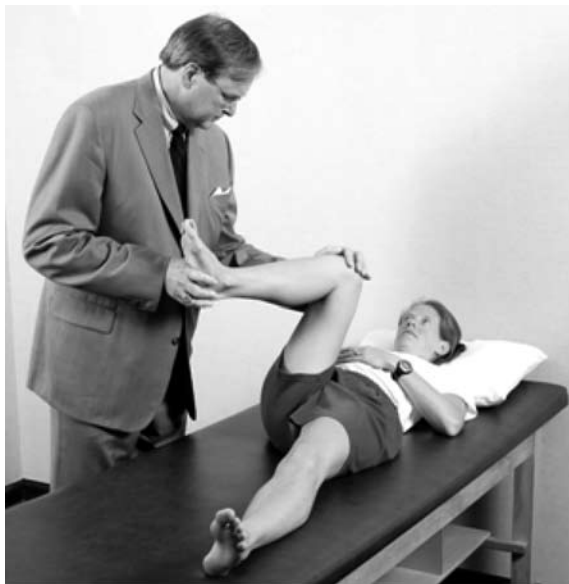The Patrick, or FABER, test (**F**lexion, **A**bduction, **E**xternal **R**otation) has been described both for stressing the sacroiliac joint to look for symptoms localized to this area and for isolating symptoms to the hip (Figure 13). Differentiating between pain localized to the sacroiliac joint and the hip is usually easy.

To perform this exam the patient lies in a “figure 4” with the affected ankle lying on the thigh of the unaffected leg. The examiner then presses on the affected knee to cause SI-joint stress. Groin pain implicates the iliopsoas as the source of pain,<sup>20</sup> and lateral pain suggests lateral FAI. To further assess for lateral FAI, passively move the patient’s leg through full flexion and extension while it is in the abducted position. Pain during this ROM signifies lateral rim impingement.

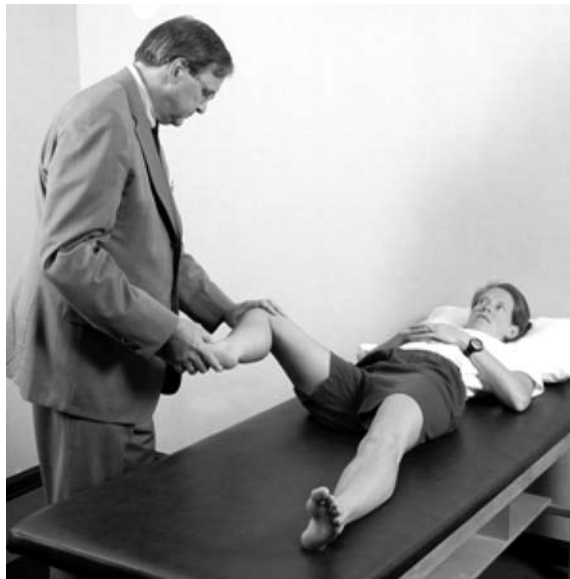The FADDIR test is performed by bringing the hip into maximal **F**lexion, **A**DDuction, and **I**nternal **R**otation. This test can be accentuated by adding an axial load with downward pressure over the knee. Pain in this position constitutes



**Figure 10** — The log-roll test is the single most specific test for hip pathology. With the patient supine, gently rolling the thigh (a) internally and (b) externally moves the articular surface of the femoral head in relation to the acetabulum but does not stress any of the surrounding extra-articular structures. (Reprinted from Byrd.<sup>10</sup>)



**Figure 11** — Forced flexion combined with internal rotation is often very uncomfortable and will usually elicit symptoms associated with even subtle degrees of hip pathology. (Reprinted from Byrd.<sup>10</sup>)



**Figure 12** — Flexion combined with abduction and external rotation is often uncomfortable and might reproduce catching-type sensations associated with labral or chondral lesions. (Reprinted from Byrd.<sup>10</sup>)

a positive FADDIR test, which might be the most sensitive indicator of FAI. The FADDIR test can also be conducted in the lateral position.

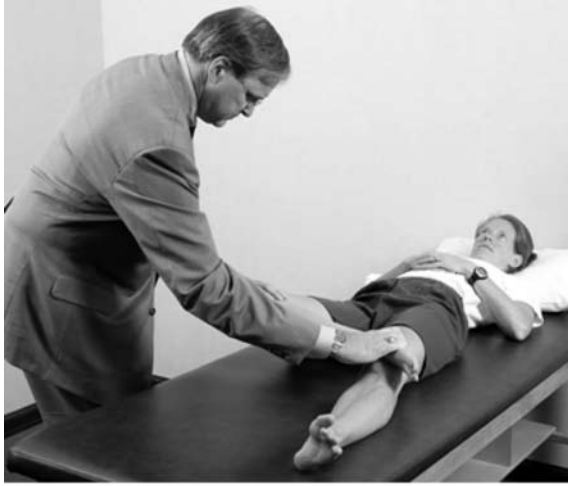The McCarthy test is performed by bringing both hips into full flexion, then extending the affected hip, first in external rotation, then in internal rotation.<sup>29</sup> A positive McCarthy test occurs with reproduction of the original pain and is most common in the case of an acetabular labrum tear.<sup>30–33</sup>

Scour's test can further delineate whether the hip pain is of an intra- or extra-articular nature. First, flex the hip and knee completely so that the knee is pointing to the shoulder. Next, rotate the hip around its arc of motion while paying special attention to any bumps, catches, or irregularities during this motion. The presence of any bumps or catches is a positive Scour's test and suggests FAI.

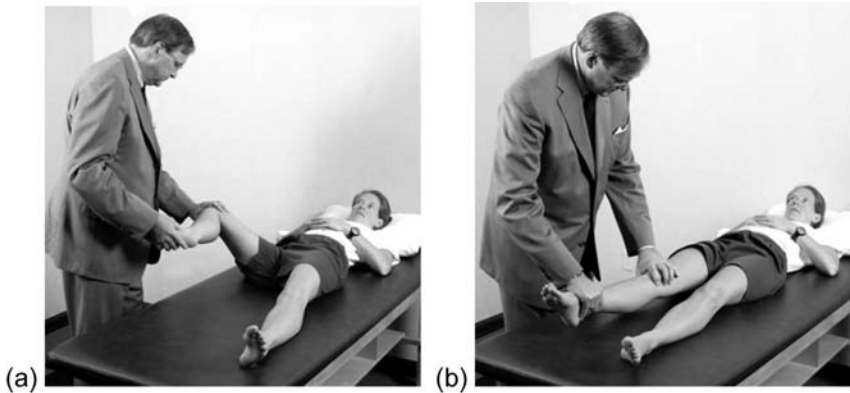
Various maneuvers can create a click or a popping sensation. These sensations might reflect an unstable labral tear or chondral fragment. The origin of these clicks or pops is often unclear, however, and they do not uniformly reflect an intra-articular lesion. The characteristic examination maneuver for creating an audible iliopsoas snap is to bring the hip from a flexed, abducted, externally rotated position (Figure 14[a]) into extension with internal rotation (Figure 14[b]).<sup>34</sup> The snapping occurs as the iliopsoas tendon transiently lodges on the anterior aspect of the hip capsule or pectineal eminence. As discussed earlier, however, the patient might better demonstrate this snapping than the examiner.

**Lateral.** With the patient in the lateral position, visual iliotibial-band snapping can be created by flexing and extending the hip, moving the abductor mechanism across



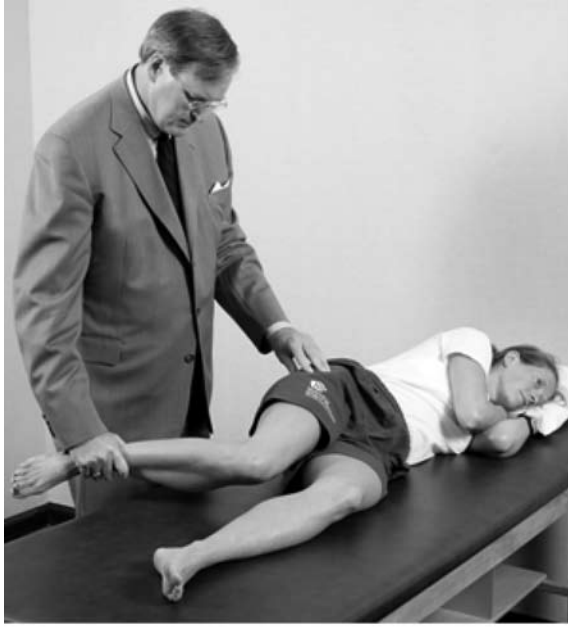

**Figure 13** — With the patient supine, the Patrick, or FABER, test is performed by crossing the ankle over the front of the contralateral knee and then forcing the knee of the involved extremity down on the table. This combination of flexion, abduction, and external rotation stresses the sacroiliac joint, and when injury or inflammation is present, it markedly enhances symptoms localized to the sacroiliac area. This same maneuver can irritate the hip joint, as well, but with distinctly different localization of symptoms. (Reprinted from Byrd.<sup>10</sup>)



**Figure 14** — Snapping of the iliopsoas tendon can be elicited as the hip is brought from (a) a flexed, abducted, externally rotated position into (b) extension with internal rotation. (Reprinted from Byrd.<sup>10</sup>)

the greater trochanter (Figure 15). Ober testing to assess for tightness of the abductor mechanism can be performed by lowering the leg on the table. Ober testing consists of 3 parts: extension, neutral, and flexion. In all 3 parts the affected leg is abducted and allowed to fall to the neutral position. Any delay in this return is



**Figure 15** — With the patient on her side, snapping of the iliotibial band can sometimes be elicited with flexion and extension of the hip. The Ober test is performed by lowering the knee to the table, assessing for tightness of the abductor mechanism. (Reprinted from Byrd.<sup>10</sup>)

considered a positive test. The extension part is performed with the knee and hip in a flexed position, with a positive test demonstrating iliotibial-band contracture. The neutral part is performed with the knee flexed but the hip in a neutral position, with a positive test demonstrating gluteus medius contracture or tear. The flexion part is performed with the patient's torso rotated so that both shoulders are flat on the table while the legs are still in the lateral position. The knee should be fully extended with the hip flexed; a positive flexion test demonstrates gluteus maximus contracture.

To perform the FADDIR test in the lateral position, stand behind the patient and place a supporting hand under his or her knee while using the other hand to palpate the hip (place the index finger on the anterior portion of the hip with the thumb pointing toward the posterior). Have the patient flex, adduct, and internally rotate the leg to elicit pain or discomfort. If any pain or discomfort occurs, the test is thought to be positive.

The final part of the lateral examination is the abduction-extension-external-rotation test. With the knee fully extended, abduct the leg 30° with no rotation and flex the hip 10°. Externally rotate the leg and place forward pressure on the greater trochanter while bringing the leg from 10° flexion to full extension. If pain occurs with the anterior pressure and abates in its absence, the test is positive. A positive abduction-extension-external-rotation test might indicate anterior acetabular anteversion, iliofemoral ligament strain, or anterior instability of the hip.<sup>15</sup> Patients

who are positive for this test should also be assessed for generalized ligamentous laxity.

**Prone.** Ely's test in the prone position can demonstrate rectus femoris contracture. The affected leg is flexed at the knee until the lower leg is as close to the upper leg as possible. If the pelvis and buttocks move upward, the test is positive, suggesting rectus femoris contracture.<sup>18</sup> Ely's test is used in contrast to the modified Thomas test discussed previously, which tests for iliopsoas contracture, a condition that can be easily confused with rectus femoris contracture.

## Radiography and Advanced Imaging

Although many hip complaints might not necessitate radiologic study,<sup>11</sup> a familiarity with the typical radiography protocol of the hip is important. When diagnostics are required, radiographs are an essential first step. A standard anteroposterior (A-P) pelvic X-ray is used to compare the affected side with the unaffected side. Bilateral Dunn or cross-table lateral radiographs can detect abnormalities of the anterior and anterolateral femoral neck. Although X-rays might not show intra-articular pathology, they are very important in assessing joint morphology. These images might identify predisposing factors ranging from dysplasia to impingement and are an essential step in evaluating intra-articular disorders.

Magnetic resonance imaging (MRI) is valuable in evaluating the cartilage and labrum of the hip joint, as well as identifying other painful processes such as loose bodies, avascular necrosis, and tumors. MRI with intra-articular gadolinium, also known as magnetic resonance arthrogram (MRA), provides superior visualization of the cartilage, as well as the labrum, but might detect lesions that are not clinically relevant. It is important to note that not all MRIs are equal. Open MRIs or MRIs of the whole pelvis provide extremely low-resolution images of the hip and are therefore unreliable in assessing the labrum and other soft-tissue structures. The most useful form is an MRA performed under a high-field magnet (>1.5 Teslas) focused specifically on the hip.

A diagnostic intra-articular injection is a crucial step in distinguishing intra-articular pathology from extra-articular pain. Relief of pain confirms an intra-articular source of pain, and lack of pain relief suggests an extra-articular source. When MRA is performed, anesthetic should be injected along with the intra-articular contrast, allowing the study to double as a diagnostic injection. It should be noted that occasionally the contrast can cause irritation of the joint, making the results of a simultaneous diagnostic injection ambiguous. When the source of pain is unclear, a separate diagnostic injection can therefore be invaluable.

In cases of bony abnormalities, CT scan can complement the use of magnetic resonance. Three-dimensional CT scans are especially helpful in assessing the bony morphology and anatomy of impingement and in planning arthroscopic decompression.

Finally, bone scans can play a role in evaluating hip pain. They are relatively inexpensive and do not rely on sophisticated technology, making them particularly useful in locations where a high-field MRI or MRA is not available. A bone scan can be a useful tool to survey the areas surrounding the hip and might detect injuries such as stress fractures that can occur in multiple sites.

## Conclusions

Historically, hip-joint problems in athletes have been largely neglected because of a combination of factors including poor assessment skills and the absence of interventional methods to address these problems. Arthroscopy has defined the existence of numerous intra-articular disorders that previously went undetected and untreated. This information has served to enhance clinical assessment skills and has stimulated advances in investigative studies.<sup>4</sup> By using a thoughtful approach and methodical examination techniques, clinicians can detect most hip-joint problems. Keeping an open mind during the investigation is also of great importance. So-called tunnel vision can lead to missed diagnosis of concomitant problems, which can lead to worse outcomes, especially in the common case of copresenting hip and back pathology.<sup>6</sup> In addition, the conclusions of the physical examination and radiology should be combined with knowledge of the patient's age, lifestyle, aspirations, and physical requirements. A proper treatment strategy can then be implemented, including the role of conservative measures and interventional methods based on an accurate diagnosis.

## References

1. Ganz R, Parvizi J, Beck M, Leunig M, Notzli H, Siebenrock KA. Femoroacetabular impingement: a cause for osteoarthritis of the hip. *Clin Orthop Relat Res.* 2003;(417):112–120.
2. Byrd JW, Jones KS. Prospective analysis of hip arthroscopy with 2-year follow-up. *Arthroscopy.* 2000;16(6):578–587.
3. Byrd JW, Jones KS. Hip arthroscopy in athletes. *Clin Sports Med.* 2001;20(4):749–761.
4. Byrd JW, Jones KS. Diagnostic accuracy of clinical assessment, magnetic resonance imaging, magnetic resonance arthrography, and intra-articular injection in hip arthroscopy patients. *Am J Sports Med.* 2004;32(7):1668–1674.
5. Longjohn D, Dorr L. Soft tissue balance of the hip. *J Arthroplasty.* 1998;13(1):97–100.
6. Brown MD, Gomez-Marin O, Brookfield KF, Li PS. Differential diagnosis of hip disease versus spine disease. *Clin Orthop Relat Res.* 2004;419:280–284.
7. Scopp JM, Moorman CT. The assessment of athletic hip injury. *Clin Sports Med.* 2001;20(4):647–659.
8. Byrd JW. Hip morphology and related pathology. In: Johnson DH, Pedowitz RA, eds. *Practical Orthopaedic Sports Medicine and Arthroscopy.* Philadelphia, PA: Lippincott Williams & Wilkins; 2007:491–503.
9. O'Leary JA, Berend K, Vail TP. The relationship between diagnosis and outcome in arthroscopy of the hip. *Arthroscopy.* 2001;17(2):181–188.
10. Byrd JW. Physical examination. In: Byrd JW, ed. *Operative Hip Arthroscopy.* 2nd ed. New York, NY: Springer; 2005:36–50.
11. Margo K, Drezner J, Motzkin D. Evaluation and management of hip pain: an algorithmic approach. *J Fam Pract.* 2003;52(8):607–617.
12. Aufranc O. The patient with a hip problem. In: Aufranc O, ed. *Constructive Surgery of the Hip.* St. Louis, MO: CV Mosby; 1962:15–49.
13. McCarthy J. *Early Hip Disorders: Advances in Detection and Minimally Invasive Treatment.* Boston, MA: Springer; 2003.
14. Byrd JW. Snapping hip. *Oper Tech Sports Med.* 2005;13(1):46–54.

15. Martin H. Clinical examination of the hip. *Oper Tech Orthop.* 2005;15:177–181.
16. Philippon MJ. Hip instability in the athlete. *Oper Tech Sports Med.* 2007;15(4):189–194.
17. Greene WB, Heckman JD, eds. *The Clinical Measurement of Joint Motion.* Rosemont, IL: American Academy of Orthopaedic Surgeons; 1994.
18. Braly BA, Beall DP, Martin HD. Clinical examination of the athletic hip. *Clin Sports Med.* 2006;25:199–210.
19. Troum OM, Crues JV. The young adult with hip pain: diagnosis and medical treatment. *Clin Orthop Relat Res.* 2004;418:9–17.
20. Reider B, Martel JM. Pelvis, hip, and thigh. In: Hoppenfeld S, Hutton R, eds. *Physical Examination of the Spine and Extremities.* Upper Saddle River, NJ: Prentice Hall; 1999:143–169.
21. Hilton J. *Rest and Pain.* London: Bell; 1863.
22. Hoppenfeld S, Hutton R. Physical examination of the hip and pelvis. In: Hoppenfeld S, Hutton R, eds. *Physical Examination of the Spine and Extremities.* Upper Saddle River, NJ: Prentice Hall; 1976:143–169.
23. Jakubowicz M. Topography of the femoral nerve in relation to components of the iliopsoas muscle in human fetuses. *Folia Morphol (Praha).* 1991;50(1-2):91–101.
24. Ritter JW. Femoral nerve “sheath” for inguinal paravascular lumbar plexus block is not found in human cadavers. *J Clin Anesth.* 1995;7(6):470–473.
25. Robinson DE, Ball KE, Webb PJ. Iliopsoas hematoma with femoral neuropathy presenting a diagnostic dilemma after spinal decompression [case report]. *Spine.* 2001;26(6):E135–E138.
26. Meyers WC, Foley DP, Garrett WE, Lohnes JH, Mandlebaum BR. Management of severe lower abdominal or inguinal pain in high-performance athletes. PAIN (Performing Athletes with Abdominal or Inguinal Neuromuscular Pain Study Group). *Am J Sports Med.* 2000;28(1):2–8.
27. Evans RC. *Illustrated Essentials in Orthopedic Physical Assessment.* St. Louis, MO: CV Mosby; 1994.
28. Hoppenfeld S. *Physical Examination of the Spine and Extremities.* Upper Saddle River, NJ: Prentice Hall; 1976.
29. McCarthy J. *Hip Arthroscopy: When It Is and When It Is Not Indicated.* Boston, MA: AAOS Instructional Course Lectures; 2004:53.
30. Farjo LA, Glick JM, Sampson TG. Hip arthroscopy for acetabular labral tears. *Arthroscopy.* 1999;15(2):132–137.
31. Fitzgerald RH, Jr. Acetabular labrum tears. diagnosis and treatment. *Clin Orthop Relat Res.* 1995; (311):60–68.
32. Lage LA, Patel JV, Villar RN. The acetabular labral tear: an arthroscopic classification. *Arthroscopy.* 1996;12(3):269–272.
33. McCarthy JC, Noble PC, Schuck MR, Wright J, Lee J. The Otto E. Aufranc Award: the role of labral lesions to development of early degenerative hip disease. *Clin Orthop Relat Res.* 2001; (393):25–37.
34. Byrd JW. Evaluation and management of the snapping iliopsoas tendon. *Instr Course Lect.* 2006;55:347–355.