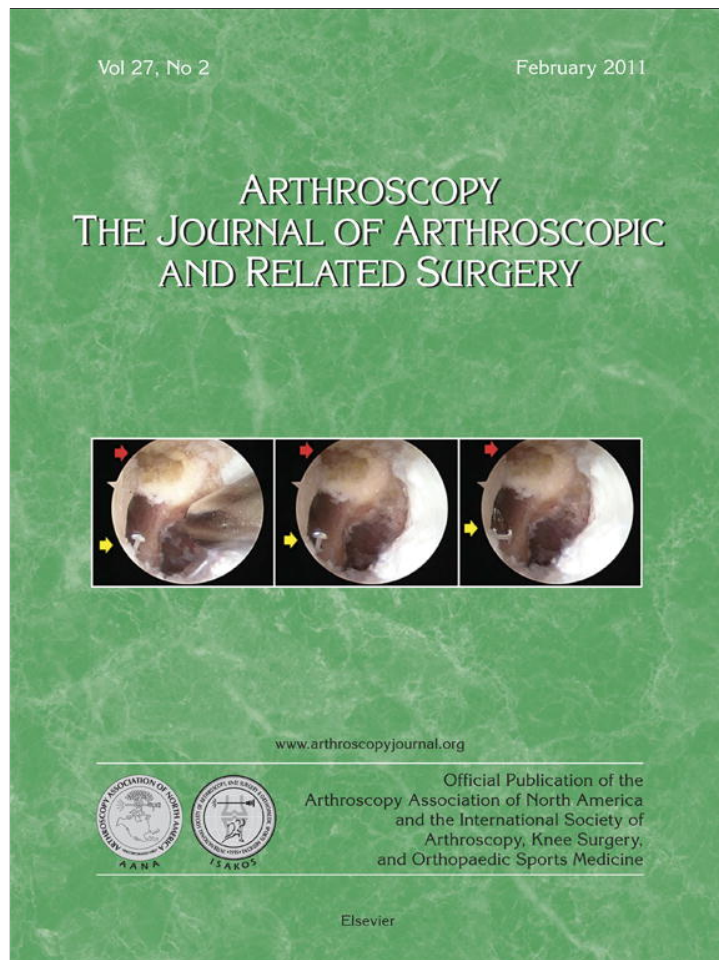


Provided for non-commercial research and education use.  
Not for reproduction, distribution or commercial use.



This article appeared in a journal published by Elsevier. The attached copy is furnished to the author for internal non-commercial research and education use, including for instruction at the authors institution and sharing with colleagues.

Other uses, including reproduction and distribution, or selling or licensing copies, or posting to personal, institutional or third party websites are prohibited.

In most cases authors are permitted to post their version of the article (e.g. in Word or Tex form) to their personal website or institutional repository. Authors requiring further information regarding Elsevier's archiving and manuscript policies are encouraged to visit:

<http://www.elsevier.com/copyright>

## Systematic Review With Video Illustration

## Open Surgical Dislocation Versus Arthroscopy for Femoroacetabular Impingement: A Comparison of Clinical Outcomes

Itamar B. Botser, M.D., Thomas W. Smith Jr., B.S., Rima Nasser, M.D., and Benjamin G. Domb, M.D.

**Purpose:** Over the last decade, the surgical treatment of femoroacetabular impingement (FAI) has evolved as surgical techniques through arthroscopy, open surgical dislocation, and combined approaches have been developed. The purpose of this systematic review was to evaluate and compare the clinical results of available surgical approaches for FAI. **Methods:** A review of the literature was performed through the PubMed database and related articles' reference lists. Inclusion criteria were (1) all patients treated for FAI, (2) Level I, II, III, or IV study design, and (3) written in the English language. Case reports and studies involving patients with acetabular dysplasia were excluded. **Results:** Overall, 1,299 articles fit our keyword search criteria. Of these, 26 articles reported clinical outcomes, using 3 surgical modalities: open surgical dislocation, arthroscopic, and combined approaches. In compiling the data in these articles, we analyzed the outcomes of a total 1,462 hips in 1,409 patients. The most published surgical method was arthroscopy, which included 62% of the patients. Labral repair was performed more frequently in open surgical dislocation (45%) and combined approach (41%) procedures than in arthroscopies (23%). Mean improvement in the modified Harris hip score after surgery was 26.4 for arthroscopy, 20.5 for open surgical dislocation, and 12.3 for the combined approach. A higher rate of return to sport was reported for arthroscopy in professional athletes than for open surgical dislocation. Overall complication rates were 1.7% for the arthroscopic group, 9.2% for the open surgical dislocation group, and 16% in the combined approach group. **Conclusions:** All 3 surgical approaches led to consistent improvements in patient outcomes. Because a wide variety of subjective hip questionnaires were used, direct comparisons could not be made in many cases, and none of the approaches could be clearly shown to be superior to the others. However, it seems that, overall, the arthroscopic method had the lowest complication and fastest rehabilitation rate. **Level of Evidence:** Level III, systematic review.

From Hinsdale Orthopaedics Associates (I.B.B., T.W.S., R.N., B.G.D.), Hinsdale, Illinois; and the Loyola University Stritch School of Medicine (I.B.B., B.G.D.), Chicago, Illinois, U.S.A.

B.G.D. is a consultant of Arthrex. The other authors report no conflict of interest.

Received October 25, 2010; accepted November 5, 2010.

Address correspondence and reprint requests to Benjamin G. Domb, M.D., Orthopaedics Associates, 1010 Executive Ct, Ste 250, Westmont, IL 60559, U.S.A. E-mail: [bendomb@yahoo.com](mailto:bendomb@yahoo.com)

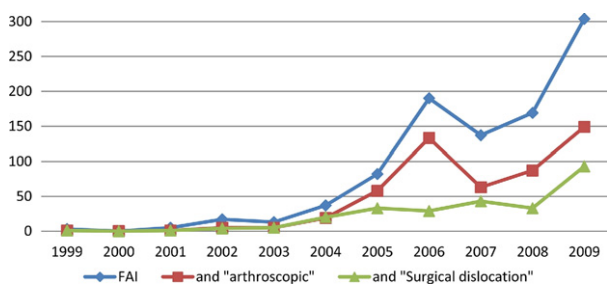
© 2011 by the Arthroscopy Association of North America

0749-8063/10623/\$36.00

doi:10.1016/j.arthro.2010.11.008

Note: To access the video accompanying this report, visit the February issue of *Arthroscopy* at [www.arthroscopyjournal.org](http://www.arthroscopyjournal.org).

The term “femoroacetabular impingement (FAI)” was first coined in the English-language literature in 1999.<sup>1</sup> A major advance in the understanding of FAI came with the development of the open surgical dislocation technique, as described by Ganz et al.<sup>2</sup> in 2001. Open surgical dislocation was previously considered the gold standard of surgical treatment for this condition. Subsequently, technologic advancements in arthroscopic technique made an arthroscopic approach to FAI possible.<sup>3-6</sup> More recently, some authors have suggested a combined arthroscopic and mini-open approach.<sup>7-9</sup> Today, arthroscopic surgery is an increasingly common practice for correction of bony pathologies and labral tears in FAI.



**FIGURE 1.** Search results in Google Scholar for number of articles containing the term “femoroacetabular impingement” by year. Separate numbers for search terms “femoroacetabular impingement and arthroscopic” and “femoroacetabular impingement and surgical dislocation” are shown in red and green, respectively.

As a new concept, FAI was the focus of much research and many publications over the last decade. Figure 1 presents the exponential growth of publications containing the term “femoroacetabular impingement” found in a search performed in Google Scholar. The number of publications grew from only 5 publications in 2001 to over 300 in 2009. After 2004, the rate of publication on “femoroacetabular impingement and arthroscopic” outstripped that of “femoroacetabular impingement and surgical dislocation.”

Each one of the different surgical approaches for FAI has its own advantages and disadvantages (Table 1). The open dislocation approach offers almost 360° of joint access. It also allows the use of a spherical template for the femoral osteoplasty, an

advantage in guiding and accurate spherical osteoplasty. This method, however, is a major operation, which necessitates the use of a trochanteric osteotomy and hip joint dislocation. The arthroscopic approach is minimally invasive, with a fast rehabilitation course; on the other hand, the procedure requires the use of traction, and access to certain areas of the joint may be challenging (Video 1, available at [www.arthroscopyjournal.org](http://www.arthroscopyjournal.org)). The combined mini-open approach with arthroscopic assistance is a hybrid approach. It is more invasive than the arthroscopic approach, but it does not require hip dislocation or trochanteric osteotomy as in surgical dislocation.

The purpose of this systematic literature review was to compare the clinical results and complication rates of these 3 surgical approaches in the treatment of FAI. In addition, the appropriate surgical indications for each approach will be assessed.

**METHODS**

Two independent reviewers (I.B.B. and T.W.S.) performed a search on PubMed for articles that contained at least 1 of the following terms: hip impingement, hip arthroscopy, femoral acetabular impingement, femoroacetabular impingement, surgical dislocation, or hip pain. The search was limited to articles that were published between 1999, the year FAI was described, and June 2010.<sup>1</sup> In addition, reference lists from the relevant articles were retrieved to identify any addi-

**TABLE 1.** Advantages and Disadvantages of Open and Arthroscopic Approaches to FAI Treatment

	Advantages	Disadvantages
Open surgical dislocation	<ul style="list-style-type: none"> <li>● Good visualization of joint</li> <li>● 360° joint access</li> <li>● Enables treatment of all pathologies</li> <li>● Templates can be used for femoral osteoplasty to ensure precise sphericity</li> </ul>	<ul style="list-style-type: none"> <li>● Major operation</li> <li>● Soft-tissue damage</li> <li>● Trochanteric osteotomy—risk of nonunion and hardware pain</li> <li>● Need to sacrifice ligamentum teres</li> <li>● Increased blood loss</li> <li>● Longer rehabilitation</li> </ul>
Combined approach	<ul style="list-style-type: none"> <li>● Easy visualization of femoral neck</li> <li>● No dislocation or trochanteric osteotomy</li> </ul>	<ul style="list-style-type: none"> <li>● Difficult to visualize intra-articular or superior parts of femoral neck</li> <li>● Cannot use spherical templates</li> <li>● Blood loss and scar associated with open surgery</li> </ul>
Arthroscopic surgery	<ul style="list-style-type: none"> <li>● Minimally invasive</li> <li>● Outpatient surgery</li> <li>● Minor soft-tissue damage</li> <li>● Faster rehabilitation</li> <li>● Easy approach to peripheral compartment and soft tissues</li> </ul>	<ul style="list-style-type: none"> <li>● Traction complications—genital and perineal injury, pudendal neurapraxia</li> <li>● Difficult access to ligamentum teres and inferior portion of joint</li> <li>● LFCN neurapraxia (portal injury)</li> <li>● Abdominal compartment syndrome</li> </ul>

Abbreviation: LFCN, lateral femoral cutaneous nerve.

**TABLE 2.** *Inclusion and Exclusion Criteria*

Inclusion Criteria	Exclusion Criteria
Surgical treatment for FAI	Case reports
Level of Evidence I-IV	Severe acetabular dysplasia (<20° lateral center-edge angle)
Written in English	Involvement of periacetabular osteotomy
	Isolated labral treatment (without addressing FAI)

tional studies of interest. By use of this search method, 1,299 articles were found. All citations were imported to Zotero version 2.0 (Center for History and New Media, Fairfax, VA) to share the search results. All studies were reviewed by I.B.B. and T.W.S. Full-text publications were obtained for relevant studies that had potential to meet our inclusion criteria: (1) surgical treatment for FAI, (2) Level of Evidence I through IV, and (3) written in English.

Articles were excluded if they were based on case reports or if patients had severe acetabular dysplasia. Periacetabular osteotomy, which has been published as an alternative for the treatment of FAI,<sup>10</sup> was also excluded. Articles that addressed only labral tears, but not FAI, were excluded as well (Table 2).

## RESULTS

Of the 1,299 articles found according to our keywords, a total of 26 fit our inclusion criteria. Eight studies reported the use of the open surgical dislocation<sup>11-18</sup>; fifteen, the use of the arthroscopic technique<sup>3-7,19-28</sup>; and four, the combined mini-open arthroscopic-assisted method.<sup>7-9,29</sup> One study had 2 groups: (1) arthroscopic and (2) combined arthroscopic and mini-open.<sup>7</sup> Eight were prospective studies, whereas nineteen were retrospective. Regarding Level

of Evidence, 1 study was Level II,<sup>8</sup> 2 were Level III,<sup>14,25</sup> and the remaining 23 were Level IV.

These 26 studies included the results of 1,462 hips in 1,409 patients. Of the hips, 900 were treated arthroscopically, 304 with the open dislocation method, and 258 by the mini-open method (Table 3). The mean age was 32.7 years (range, 11 to 68 years). Of the patients, 63% were male patients, and the right side was involved in 55% of the cases. The mean time from onset of symptoms to surgery was reported in only 8 studies and was 28 months on average. The mean follow-up time reported was 27 months on average (range, 3 to 144 months).

Labral repair was performed in 30% of the cases overall but was done in only 23% of the arthroscopic cases. In contrast, repair was performed in 45% of surgical dislocations and 41% of the combined approach cases. Of arthroscopies, 54% involved labral debridement, a higher number than for open (41%) and combined (33%) approaches. Microfracture was reported mostly in arthroscopic cases, which comprised 160 of the 166 microfractures reported.

There were many scoring methods used to measure the success of the hip surgeries (Table 4), including the modified Harris Hip Score (mHHS) as described by Byrd and Jones,<sup>30</sup> the Hip Outcome Score for Activity of Daily Living and Sport Specific Subscale,<sup>31</sup> the Merle d'Aubigne Score,<sup>32</sup> the Non Arthritic Hip Score (NAHS),<sup>33</sup> the Western Ontario and McMaster Universities Osteoarthritis Index,<sup>34</sup> and the Japanese Orthopaedic Association Scoring System.<sup>24</sup> The most popular scoring system was the mHHS, which was used in 13 of 26 articles. The mHHS was mostly used for the arthroscopic method (9 of 15), whereas the Merle d'Aubigne Score was used mostly for open surgeries: 4 of 8 articles using an open method.

Comparisons between approaches for each scoring system are shown in Table 4. Of the 6 scoring systems used, only the mHHS, Merle d'Aubigne, and Western

**TABLE 3.** *Patient Demographics*

	Arthroscopic	Open	Mini-Open	Total
Patients (n)	881	287	241	1,409
Hips (n)	900	304	258	1,462
Articles (n)	15	8	4	26*
Prospective studies (n)	4	2	2	8
Male patients (n)	64.93% (572)	61.00% (147)	60.08% (152)	63.35% (871)
Mean age (yr) (range)	33.3 (11-68)	29.1 (14-54)	35.1 (14-57)	32.7 (11-68)
Follow-up (months)	20.7	30.5	45.7	27
Minimum follow-up	3	4.2	15.6	3
Maximum follow-up	96	144	104.4	144

\*One article had 2 groups, mini-open and arthroscopic<sup>7</sup>; therefore each group is included in a different column.

**TABLE 4.** FAI Surgical Results According to Different Hip-Specific Questionnaires: mHHS,<sup>30</sup> HOS ADL and Sport-Specific Subscale,<sup>31</sup> Merle d'Aubigne Score,<sup>32</sup> NAHS,<sup>33</sup> WOMAC,<sup>34</sup> and JOA Scoring System<sup>24</sup>

	Arthroscopic	Open	Mini-Open	Total
<b>mHHS</b>				
Articles (n)	9	2	2	13
Patients (n)	408	111	41	560
Preoperative score (mean)	61.31	71.50	64.90	63.15
Postoperative score (mean)	88.59	92.00	85.90	88.69
Improvement (mean)	26.40	20.50	12.30	24.55
<b>HOS ADL</b>				
Articles (n)	2	0	0	2.00
Patients (n)	129	0	0	129
Preoperative score (mean)	53.00			53.00
Postoperative score (mean)	90.90			90.90
Improvement (mean)	37.90			37.90
<b>HOS sport</b>				
Articles (n)	3	0	0	3
Patients (n)	170	0	0	170
Preoperative score (mean)	47.33			47.33
Postoperative score (mean)	77.67			77.67
Improvement (mean)	30.33			30.33
<b>NAHS</b>				
Articles (n)	4	0	1	5
Patients (n)	212	0	100	312
Preoperative score (mean)	62.14		54.80	60.67
Postoperative score (mean)	85.25		83.90	84.98
Improvement (mean)	23.11		29.10	24.31
<b>Japanese Orthopaedic Association</b>				
Articles (n)	3	0	0	3
Patients (n)	90	0	0	90
Preoperative score (mean)	15.62			15.62
Postoperative score (mean)	2.38			2.38
Improvement (mean)	1.62			1.62
<b>Merle d'Aubigne</b>				
Articles (n)	1	4	1	6
Patients (n)	38	115	117	270
Preoperative score (mean)	14.60	10.62	16.08	11.97
Postoperative score (mean)	16.70	13.48	17.44	14.67
Improvement (mean)	2.10	3.50	1.36	2.91
<b>WOMAC</b>				
Articles (n)	1	1	1	3
Patients (n)	38	37	117	192
Preoperative score (mean)	55.00	61.20	65.36	60.52
Postoperative score (mean)	75.00	81.40	91.76	82.72
Improvement (mean)	20.00	20.20	26.40	22.20

Abbreviations: HOS ADL, Hip Outcome Score for Activity of Daily Living; WOMAC, Western Ontario and McMaster Universities Osteoarthritis Index; JOA, Japanese Orthopaedic Association.

Ontario and McMaster Universities Osteoarthritis Index scores were used in at least 1 study for each of the 3 approaches. Therefore direct comparisons between the approaches were not always possible. However, the mHHS was the most frequently used scoring system and therefore the most appropriate for direct comparison. Mean improvement in mHHS score after surgery was 26.4 for arthroscopy, 20.5 for open surgical dislocation, and 12.3 for the combined approach.

Three studies that concentrated on an athletic population used the percentage of return to competitive play<sup>26</sup> and time to return to play<sup>13,27</sup> as a measure of treatment success. Three studies reported the result of arthroscopic treatment for FAI in professional athletes. One showed that of 45 athletes treated for FAI arthroscopically, 93% returned to play professionally after surgery. However, at a mean follow-up of 1.6 years, only 78% continued to play professionally.<sup>26</sup>



**TABLE 5.** FAI Surgical Complication Rate as Reflected by 26 Articles Found

	Arthroscopic	Open	Mini-Open	Total (N = 1,462)
Hips (n)	900	304	258	1,462
HO	10 (1.1%)	10 (3.2%)	1 (0.3%)	21 (1.4%)
Pudendal transient neurapraxia	1	0	1	2
LFCN transient neurapraxia	3 (0.3%)	0	28 (10.8%)	31 (2.1%)
Sciatic neurapraxia	1	0	0	1
Motion	1	0	0	1
AVN	0	0	0	0
Trochanteric fixation complication*	0	17 (5.5%)	0	17 (1.1%)
Persistent pain	0	1	13 (5%)	14 (1%)
Total	16 (1.7%)	28 (9.2%)	43 (16%)	87 (5.9%)

Abbreviations: LFCN, lateral femoral cutaneous nerve; AVN, avascular necrosis.

\*Fixation failure, nonunion, or persistent pain.

The second study reported the results of 28 professional hockey players who were treated arthroscopically for FAI.<sup>27</sup> All players returned to professional play after surgery. The mean number of National Hockey League games played after surgery was 94, and the mean time to return to practice was 3.8 months. A third study, by Singh and O'Donnell,<sup>28</sup> on 24 Australian Football League players who underwent arthroscopic surgery for FAI, reported that 74% of patients had cartilage loss or cartilage softening. The mean mHHS improved from 86 to 97 two years after surgery, and the NAHS improved from 81 to 99 two years after surgery. Of 24 players, 23 returned to top-level Australian Football League play. One player subsequently retired a year after hip surgery because of a chronic knee injury. In contrast, Bizzini et al.<sup>13</sup> reported the results of open surgical dislocation for FAI in 5 professional hockey players; return to unrestricted team practice was achieved after 6.7 months on average, and the mean time to return to play was 9.6 months.

The total complication rate for the operative FAI treatment was 5.9%, and the specific complications by approach are summarized in Table 5. By approach, complication rates were 1.7% for the arthroscopic group, 9.2% for the open surgical dislocation group, and 16% in the combined approach group. Heterotrophic ossification (HO) was the most common complication and was reported in all surgical methods, with a prevalence of 0.3% in the combined approach group, 1.1% in the arthroscopic group, and 3.2% in the open group. The greater trochanteric osteotomy was the most common cause of complications in the open surgical dislocation group (5.5%), and persistent pain after the surgery was the most prevalent complication in the combined approach group (5%).

Revisions were required in 36 cases: 13 (1.4%) in the arthroscopic group, 18 (7%) in the mini-open group, and 5 (1.6%) in the open group. The main reason for revision in the open group was pain around the trochanteric fixation; in the mini-open approach group, the revisions were most frequently done for persistent hip pain<sup>8</sup> (Table 6).

**TABLE 6.** Key Points of Article

- 1,299 articles were reviewed according to keyword searches and reference lists
- 26 studies met inclusion criteria: 8 open surgical dislocation, 15 arthroscopic, and 4 combined mini-open (1 study had 2 groups)
- A total of 1,462 hips in 1,409 patients were treated with 3 approaches: 900 hips were treated arthroscopically, 304 hips by open surgical dislocation, and 258 hips by combined approach
- The mean improvement in mHHS was 26.4 for arthroscopy, 20.5 for open surgical dislocation, and 12.3 for the combined approach
- The total complication rate reported was 5.9%; the lowest rate for the arthroscopic approach was 1.7% as compared with 9.2% and 16% for the open surgical dislocation and combined mini-open approaches, respectively
- The open surgical dislocation approach gives the best visualization of the hip joint, allows for the use of a spherical template, and has the potential to be the most accurate approach
- The combined mini-open approach avoids the risks associated with both femoral head dislocation and trochanteric osteotomy, which are necessarily included in the open approach
- The arthroscopic approach is a minimally invasive approach with the fastest rehabilitation rate and the lowest incidence of complications and revisions

## DISCUSSION

Over the last decade, there has been significant development in the understanding and treatment of FAI. Today, FAI is considered a bony morphologic variant predisposing the joint to intra-articular pathology that may become symptomatic.<sup>5</sup> It has been shown that labral tears and chondral lesions may be common pain generators that result from FAI. Hence, it has been proposed that surgical treatment should not only address the intra-articular pathology, which is the source of pain, but should also correct the bony deformities, which are the cause of the impingement.<sup>7</sup>

The open surgical dislocation approach to the hip joint was perhaps one of the innovations that paved the way toward popularization of successful surgical treatment of FAI. The approach made possible circumferential access to the femoral head and acetabulum, without significant risk of avascular necrosis. In 2004 midterm results for FAI treatment through the open approach were published.<sup>11</sup> Of 19 patients, 13 rated their results as excellent to good with a mean follow-up of 4.7 years. Of the patients, 5 (26%) had a total hip replacement 3 years after the open surgery. All patients had severe acetabular cartilage damage; 2 with Tonnis grade II osteoarthritis and 2 with Tonnis grade I osteoarthritis.<sup>35</sup> One other patient had an untreated ossified labrum.

The open surgical dislocation approach allows 360° visualization of the femoral head and acetabulum. Moreover, the use of a spherical template to ensure femoral head sphericity during an osteoplasty is feasible. However, the open surgical dislocation is not flawless. Most of its complications are related to the trochanteric osteotomy and include fixation failure, trochanteric nonunion, and more commonly, pain. Thus it is common for surgeons to remove the hardware from previous osteotomies 1 year postoperatively. Beaulé et al.<sup>12</sup> reported the results of a series of 37 hips treated for FAI. Nine hips had pain over the greater trochanter with persistent bursitis. Screws were removed at a mean of 8 months postoperatively. All patients became asymptomatic and returned to full activity after the screws were removed.

Although the open surgical dislocation is a safe approach that spares the vascularity of the femoral head, its safety was not yet established at the time that the combined approach came into increasing use around 1999.<sup>8</sup> By use of a minimal anterior approach to the hip combined with arthroscopy and fluoroscopy, hip dislocation and trochanteric osteotomy could be avoided.<sup>7-9,29</sup> In 2009 and 2010, 4 articles published

their results of the combined approach.<sup>7-9,29</sup> Laude et al.<sup>8</sup> published the clinical results of 100 hips with a mean follow-up of almost 5 years. They assessed patients clinically using the NAHS. At the last follow-up, the mean NAHS increased by 29.1 points. Of this group, 13 required an arthroscopic revision because of persistent pain. Fracture of the femoral neck was reported in 1 case in which the patient was allowed full weight bearing on the first day postoperatively. After this case, the weight-bearing protocol was changed. Nevertheless, this approach involves complications including pain associated with the open approach as well as complications resulting from the traction applied during arthroscopy. In addition, the mini-open component of the approach offers less visualization of the femoral head and acetabulum than the open surgical dislocation.

Despite its success and its importance as an innovation, open surgical dislocation is a relatively invasive surgery that requires prolonged rehabilitation. The next logical step, therefore, was to develop a minimally invasive surgical approach. In 2009 Byrd and Jones<sup>5</sup> published the results of 200 patients (207 hips) who had arthroscopic treatment for FAI with a mean follow-up of 16 months (range, 12 to 24 months). Most of the patients had an isolated cam lesion (163 hips), whereas the rest had combined pincer and cam lesions (44 hips). Overall, 83% of the patients had an improved mHHS, with a mean increase of 20 points. The patients continued to improve over the course of 1 year after their surgery. One patient with Outerbridge grade IV cartilage damage was converted to a total hip replacement. The complication rate for this study was 1.5%. In another study about hip arthroscopy revision, it was noted, upon radiographic evaluation before surgery, that 36 of 37 patients had evidence of impingement that was either unaddressed or inadequately addressed at the time of index procedure.<sup>36</sup> This study and others have emphasized that although arthroscopy is minimally invasive, the incomplete or overly aggressive correction of the bony deformities may necessitate further surgery.

The overall rate of complications reported in the arthroscopic series was the lowest of the 3 groups, at 16 of 900 (1.7%). This rate is comparable to the 1.4% complication rate reported in 1,054 hip arthroscopies in 2003 by Clarke et al.<sup>37</sup> Common complications of the arthroscopic approach included sciatic, pudendal, and lateral femoral cutaneous transient nerve injuries (Table 4). Osteonecrosis of the femoral head was not reported in any of the articles. HO was reported in all 3 approaches, but its highest rate of occurrence oc-

curred with the open approach, at 3.4%. However, it should be noted that 9 of the 10 HO cases in the open group were reported in a single study<sup>15</sup> and were classified as Brooker type 1, suggesting that there may have been differences in detection or reporting of HO among studies.<sup>38</sup> For comparison, the HO rate in the arthroscopic group is only 1.1%, and 9 of the 10 cases were from 2 articles.<sup>6,25</sup>

Professional athletes have had good to excellent results with both open and arthroscopic approaches for FAI.<sup>13,26-28</sup> Both Philippon et al.<sup>26,27</sup> and Bizzini et al.<sup>13</sup> reported the clinical results of professional athletes according to their return to sport, and they showed that return occurred more rapidly with the arthroscopic method. Professional hockey players were cleared to participate in their first game at a mean of 3.9 months in the arthroscopic study,<sup>27</sup> as compared with a mean of 9.6 months in the open method study.<sup>13</sup> It should be noted that return to sport as a measure of outcomes applies to a specific population only. In addition, professional athletes may have financial interest to present positive results. Hence, the results of these studies may not be applicable to the general population.<sup>14</sup> On the other hand, current hip-specific questionnaires may not be sufficiently sensitive to assess the high level of function required in professional athletes. Illustrating this point, 1 professional hockey player had an mHHS of 100 preoperatively<sup>27</sup> but was unable to play because of pain. When the studies of professional athletes are compared, those treated arthroscopically had a higher rate of return to sport, and returned more quickly, than the 5 athletes included in the article on open surgical dislocations by Bizzini et al. Although conclusions are limited because of small sample size, this suggests that a well-performed arthroscopy may have advantages over surgical dislocation in the athletic population.

The main limitation of this systematic review was the lack of prospective studies that directly compare the approaches. Furthermore, the existing studies use a heterogeneous mix of outcome scores. Six different hip-specific questionnaires were used in 26 articles (mHHS,<sup>30</sup> Hip Outcome Score for Activity of Daily Living and Sport Specific Subscale,<sup>31</sup> Merle d'Aubigne Score,<sup>32</sup> NAHS,<sup>33</sup> Western Ontario and McMaster Osteoarthritis Index,<sup>34</sup> and Japanese Orthopaedic Association Scoring System<sup>24</sup>). Some of the investigators used more than 1 score, but direct comparison of all results was not possible because of this heterogeneity. The wide variety of scores emphasizes the need for 1 widely acceptable questionnaire that will have the ability to measure the vast range of patients.

Another limitation in the value of the comparisons presented stems from differences in surgical technique and procedure, given that surgical treatment for FAI and labral tears has evolved over the last decade. During the earlier part of the decade, the standard treatment for labral tearing was debridement. However, evidence that the labrum plays an important role in hip joint stability and the prevention of degenerative changes has suggested that labral preservation may be important.<sup>14,39</sup> In 2006 Espinosa et al.<sup>14</sup> showed more favorable results with labral refixation than with labral debridement while using the open method. Larson and Giveans<sup>25</sup> showed similar superior results of labral refixation compared with debridement using the arthroscopic method. Recently, labral reconstruction has been shown to yield positive results in patients with labral deficiency through both open surgical dislocation and the arthroscopic method.<sup>40,41</sup> Because this systematic review included studies from various time points in the evolution of surgical thinking in FAI, different techniques may have been used, irrespective of surgical approach.

The long-term follow-up results of the 3 surgical methods to treat FAI are yet to be reported. Although early recovery may be faster after arthroscopy because of its less invasive nature, it is not clear how the approaches will compare over a longer period. The open procedure may allow greater visualization and more precise correction of the bony pathology through the use of a spherical template. If such a difference in precision does indeed exist, its benefits may only manifest in the long term.

## CONCLUSIONS

Surgical treatment of FAI has shown consistent positive outcomes with all 3 approaches reviewed in this article. The heterogeneous use of different outcome scores makes direct comparisons difficult. However, the arthroscopic method showed the greatest short-term improvement in mHHS and the lowest rate of complications. It is likely that all 3 approaches may have valuable roles in the treatment of FAI. An understanding of the advantages and disadvantages of each, as well as knowledge of each approach, will enable the surgeon to select the most appropriate approach for any given surgery. Studies directly comparing the approaches, as well as longer-term follow-up, will be necessary to more clearly elucidate the respective roles of these 3 surgical approaches.



## REFERENCES

- Myers SR, Eijer H, Ganz R. Anterior femoroacetabular impingement after periacetabular osteotomy. *Clin Orthop Relat Res* 1999;93-99.
- Ganz R, Gill TJ, Gautier E, Ganz K, Krugel N, Berlemann U. Surgical dislocation of the adult hip a technique with full access to the femoral head and acetabulum without the risk of avascular necrosis. *J Bone Joint Surg Br* 2001;83:1119-1124.
- Philippon MJ, Briggs KK, Yen YM, Kuppersmith DA. Outcomes following hip arthroscopy for femoroacetabular impingement with associated chondrolabral dysfunction: Minimum two-year follow-up. *J Bone Joint Surg Br* 2009; 91:16-23.
- Philippon MJ, Yen YM, Briggs KK, Kuppersmith DA, Maxwell RB. Early outcomes after hip arthroscopy for femoroacetabular impingement in the athletic adolescent patient: A preliminary report. *J Pediatr Orthop* 2008;28:705-710.
- Byrd JW, Jones KS. Arthroscopic femoroplasty in the management of cam-type femoroacetabular impingement. *Clin Orthop Relat Res* 2009;467:739-746.
- Larson CM, Giveans MR. Arthroscopic management of femoroacetabular impingement: Early outcomes measures. *Arthroscopy* 2008;24:540-546.
- Nepple JJ, Zebala LP, Clohisey JC. Labral disease associated with femoroacetabular impingement: Do we need to correct the structural deformity? *J Arthroplasty* 2009;24:114-119.
- Laude F, Sariali E, Nogier A. Femoroacetabular impingement treatment using arthroscopy and anterior approach. *Clin Orthop Relat Res* 2009;467:747-752.
- Lincoln M, Johnston K, Muldoon M, Santore R. Combined arthroscopic and modified open approach for cam femoroacetabular impingement: A preliminary experience. *Arthroscopy* 2009;25:392-399.
- Siebenrock KA, Schoeniger R, Ganz R. Anterior femoroacetabular impingement due to acetabular retroversion. Treatment with periacetabular osteotomy. *J Bone Joint Surg Am* 2003;85:278-286.
- Beck M, Leunig M, Parvizi J, Boutier V, Wyss D, Ganz R. Anterior femoroacetabular impingement: Part II. Midterm results of surgical treatment. *Clin Orthop Relat Res* 2004;67-73.
- Beaule PE, Le Duff MJ, Zaragoza E. Quality of life following femoral head-neck osteochondroplasty for femoroacetabular impingement. *J Bone Joint Surg Am* 2007;89:773-779.
- Bizzini M, Notzli HP, Maffioletti NA. Femoroacetabular impingement in professional ice hockey players: A case series of 5 athletes after open surgical decompression of the hip. *Am J Sports Med* 2007;35:1955-1959.
- Espinosa N, Rothenfluh DA, Beck M, Ganz R, Leunig M. Treatment of femoroacetabular impingement: Preliminary results of labral refixation. *J Bone Joint Surg Am* 2006;88:925-935.
- Graves ML, Mast JW. Femoroacetabular impingement: Do outcomes reliably improve with surgical dislocations? *Clin Orthop Relat Res* 2009;467:717-723.
- Murphy S, Tannast M, Kim YJ, Buly R, Millis MB. Debridement of the adult hip for femoroacetabular impingement: Indications and preliminary clinical results. *Clin Orthop Relat Res* 2004;178-181.
- Peters CL, Erickson JA. Treatment of femoroacetabular impingement with surgical dislocation and debridement in young adults. *J Bone Joint Surg Am* 2006;88:1735-1741.
- Yun H-H, Shon W-Y, Yun J-Y. Treatment of femoroacetabular impingement with surgical dislocation. *Clin Orthop Surg* 2009;1:146-154.
- Bardakos NV, Vasconcelos JC, Villar RN. Early outcome of hip arthroscopy for femoroacetabular impingement: The role of femoral osteoplasty in symptomatic improvement. *J Bone Joint Surg Br* 2008;90:1570-1575.
- Brunner A, Horisberger M, Herzog RF. Sports and recreation activity of patients with femoroacetabular impingement before and after arthroscopic osteoplasty. *Am J Sports Med* 2009;37:917-922.
- Gedouin JE, Duperron D, Langlais F, Thomazeau H. Update to femoroacetabular impingement arthroscopic management. *Orthop Traumatol Surg Res* 2010;96:222-227.
- Horisberger M, Brunner A, Herzog RF. Arthroscopic treatment of femoral acetabular impingement in patients with preoperative generalized degenerative changes. *Arthroscopy* 2010;26:623-629.
- Kang C, Hwang D-S, Cha S-M. Acetabular labral tears in patients with sports injury. *Clin Orthop Surg* 2009;1:230-235.
- Kim KC, Hwang DS, Lee CH, Kwon ST. Influence of femoroacetabular impingement on results of hip arthroscopy in patients with early osteoarthritis. *Clin Orthop Relat Surg* 2007; 456:128-132.
- Larson CM, Giveans MR. Arthroscopic debridement versus refixation of the acetabular labrum associated with femoroacetabular impingement. *Arthroscopy* 2009;25:369-376.
- Philippon M, Schenker M, Briggs K, Kuppersmith D. Femoroacetabular impingement in 45 professional athletes: Associated pathologies and return to sport following arthroscopic decompression. *Knee Surg Sports Traumatol Arthrosc* 2007; 15:908-914.
- Philippon MJ, Weiss DR, Kuppersmith DA, Briggs KK, Hay CJ. Arthroscopic labral repair and treatment of femoroacetabular impingement in professional hockey players. *Am J Sports Med* 2010;38:99-104.
- Singh PJ, O'Donnell JM. The outcome of hip arthroscopy in Australian Football League Players: A review of 27 Hips. *Arthroscopy* 2010;26:743-749.
- Ribas M, Ledesma R, Cardenas C, Marin-Pena O, Toro J, Caceres E. Clinical results after anterior mini-open approach for femoroacetabular impingement in early degenerative stage. *Hip Int* 2010;20:36-42 (Suppl 7).
- Byrd JW, Jones KS. Prospective analysis of hip arthroscopy with 2-year follow-up. *Arthroscopy* 2000;16:578-587.
- Martin RL, Philippon MJ. Evidence of validity for the hip outcome score in hip arthroscopy. *Arthroscopy* 2007;23:822-826.
- d'Aubigne RM, Postel M. The classic: Functional results of hip arthroplasty with acrylic prosthesis. 1954. *Clin Orthop Relat Res* 2009;467:7-27.
- Christensen CP, Althausen PL, Mittleman MA, Lee JA, McCarthy JC. The nonarthritic hip score: Reliable and validated. *Clin Orthop Relat Res* 2003;75-83.
- Bellamy N, Buchanan WW, Goldsmith CH, Campbell J, Stitt LW. Validation study of WOMAC: A health status instrument for measuring clinically important patient relevant outcomes to antirheumatic drug therapy in patients with osteoarthritis of the hip or knee. *J Rheumatol* 1988;15:1833-1840.
- Tonnis D, Heinecke A. Acetabular and femoral anteversion: Relationship with osteoarthritis of the hip. *J Bone Joint Surg Am* 1999;81:1747-1770.
- Philippon MJ, Schenker ML, Briggs KK, Kuppersmith DA, Maxwell RB, Stubbs AJ. Revision hip arthroscopy. *Am J Sports Med* 2007;35:1918-1921.
- Clarke MT, Arora A, Villar RN. Hip arthroscopy: Complications in 1054 cases. *Clin Orthop Relat Res* 2003;84-88.
- Brooker AF, Bowerman JW, Robinson RA, Riley LH Jr. Ectopic ossification following total hip replacement. Incidence and a method of classification. *J Bone Joint Surg Am* 1973; 55:1629-1632.
- Ferguson SJ, Bryant JT, Ganz R, Ito K. The acetabular labrum seal: A poroelastic finite element model. *Clin Biomech (Bristol, Avon)* 2000;15:463-468.

40. Philippon MJ, Briggs KK, Hay CJ, Koppersmith DA, Dewing CB, Huang MJ. Arthroscopic labral reconstruction in the hip using iliotalibial band autograft: technique and early outcomes. *Arthroscopy* 2010;26:750-756.
41. Sierra RJ, Trousdale RT. Labral reconstruction using the ligamentum teres capitis: Report of a new technique. *Clin Orthop Relat Res* 2009;467:753-759.
42. Fry R, Domb B. Labral base refixation in the hip: Rationale and technique for an anatomic approach to labral repair. *Arthroscopy*. 2010;26:S81-S89.
43. Seldes RM, Tan V, Hunt J, Katz M, Winiarsky R, Fitzgerald RH. Anatomy, histologic features, and vascularity of the adult acetabular labrum. *Clin Orthop Relat Res* 2001:232-240.
44. Kelly BT, Philippon MJ. Arthroscopic hip anatomy. In: Callaghan JJ, Rosenberg AG, Rubash HE (eds). *The adult hip*. Ed 2. Philadelphia: Lippincott Williams & Wilkins, 2007;68-80.