

Technical Note

Endoscopic Iliopsoas Tenotomy for Iliopsoas Impingement on a Collared Femoral Prosthesis

Dror Lindner, M.D., Christine E. Stake, M.A., Youssef F. El Bitar, M.D.,
Timothy J. Jackson, M.D., and Benjamin G. Domb, M.D.

Abstract: Groin pain after total hip replacement is an uncommon event and may be the result of several causes, including iliopsoas impingement. We describe the case of a 51-year-old woman who was diagnosed with iliopsoas impingement after total hip replacement with a collared femoral stem. She did not improve despite extensive conservative treatment. She was treated by endoscopic iliopsoas tenotomy, and the surgical technique is described herein. Her preoperative groin pain and popping disappeared completely at 3 months postoperatively.

First reported by Postel in 1975,¹ iliopsoas impingement or tendinitis is an under-recognized cause of hip and groin pain after total hip replacement (THR). Since this first report, several causes have been proposed, including prominent or malpositioned acetabular components,^{2,3} retained cement,³⁻⁵ excessively long screws,^{3,6} and the presence of an acetabular cage or reinforcement ring. Additional factors that may contribute to the development of tendinitis are increased offset and leg-length discrepancy. Brew et al.⁷ reported on a case of iliopsoas impingement caused by overhang of the collar. This was the first report of a collared stem causing impingement. The patient was treated with revision of the stem to a collarless stem with resolution of the symptoms. We report on a patient who had a similar pathology, iliopsoas impingement caused by overhang of a collared femoral stem, treated by endoscopic iliopsoas tenotomy, with a favorable outcome (Tables 1 and 2).

From the American Hip Institute (D.L., C.E.S., Y.F.E.B., T.J.J., B.G.D.), Chicago, Illinois; Hinsdale Orthopaedics (C.E.S., B.G.D.), Hinsdale, Illinois; and Stritch School of Medicine, Loyola University (B.G.D.), Chicago, Illinois, U.S.A.

The authors report the following potential conflict of interest or source of funding in relation to this article: American Hip Institute; Adventist Hinsdale Hospital; MedWest; MAKO Surgical Corp; and Arthrex, Inc. No monies were directly related to writing or publication of this study.

Received January 16, 2013; accepted February 13, 2013.

Address correspondence to Benjamin G. Domb, M.D., Hinsdale Orthopaedics, 1010 Executive Ct, Ste 250, Westmont, IL 60559, U.S.A. E-mail: DrDomb@AmericanHipInstitute.org

© 2013 by the Arthroscopy Association of North America
2212-6287/1353/\$36.00

<http://dx.doi.org/10.1016/j.eats.2013.02.008>

Case Report

A 51-year-old woman presented to our office 2 years after left THR with a cementless collared stem, complaining of groin pain and painful popping. She reported groin pain immediately after surgery. Physical examination was positive for internal hip snapping and painful external rotation. A complete infection workup was negative. The patient reported no improvement in the pain despite extensive physical therapy and anti-inflammatory medication.

Radiographs showed a cementless collared femoral prosthesis with a 13-mm overhang of the collar over the femoral calcar (Fig 1). The radiographic findings combined with the clinical history and physical examination suggested that the cause of pain and popping was impingement of the iliopsoas tendon over the protruding collar.

Ultrasound showed the proximity of the iliopsoas tendon to the collar (Fig 2). This was followed by an ultrasonically guided diagnostic local anesthetic and corticosteroid injection to the iliopsoas tendon at the point of impingement between the collar and psoas tendon. This relieved the patient's symptoms for 6 weeks, thus confirming the cause of her pain.

An endoscopic iliopsoas tenotomy was performed (Fig 3); this resulted in resolution of the patient's groin pain and the painful popping. She remains pain free at 6 months postoperatively.

Surgical Technique

Under general anesthesia, the patient is placed in the supine position on a traction table (Smith & Nephew, London, England). Both feet are well secured, and a well-padded peroneal post (Smith & Nephew) is used

Table 1. Advantages and Potential Pitfalls of Endoscopic Iliopsoas Tenotomy for Iliopsoas Impingement on Collared Femoral Prosthesis

Technique Advantages	Potential Pitfalls
<ul style="list-style-type: none"> • Minimal disruption of normal anatomy • Superior visualization • Potentially decreased neurovascular complications because of improved visualization • Decreased bleeding • Fast recovery time • Does not “burn any bridges” if, eventually, a revision surgery is required 	<ul style="list-style-type: none"> • Injury to neurovascular structures during blind portal placement • Increased operative time and fluid extravasation, particularly during early part of learning curve • Scraping of prosthesis with surgical instruments

to protect the genitalia. The hip is prepared and draped in the usual fashion. By use of fluoroscopic visualization, correct portal placement is identified and 0.5% bupivacaine is injected into the subcutaneous tissues. The anterolateral portal is established first, by use of a No. 11 blade for the skin. A spinal needle is inserted through the incision, aiming toward the head–neck junction. An over-the-guidewire technique is used to insert a 70° arthroscope through a 4.5-mm cannula. A midanterior portal is established by the same over-the-guidewire technique. Through the midanterior portal, a shaver (Smith & Nephew) is introduced. By use of the shaver, scar tissue is dissected until the collar of the femoral stem is visualized. The iliopsoas tendon is seen in contact with the collar and is released with a beaver blade (Smith & Nephew) (Video 1). Additional procedures may be performed if necessary, such as inspection of the prosthesis, tissue biopsy, trochanteric bursectomy, gluteus medius inspection/repair, and iliotibial band release.

Rehabilitation and Recovery

For the first 2 weeks, the patient is kept in a hip brace (DJO Global, Vista, CA) locked at 0° to 90° of flexion at all times and is restricted to 20 lb of flat-foot weight bearing. The patient starts physical therapy on the first postoperative day. Two weeks postoperatively, the brace and crutches are discontinued

and the patient continues physical therapy with an emphasis on strengthening the gluteus medius and core muscles, as well as gradual progression of range of motion.

Discussion

Persistent pain after THR, though a rare event, may have a detrimental effect on the patient’s outcome and requires a thorough investigation. The differential diagnosis is broad; Duffy et al.⁸ have divided it into intrinsic and extrinsic causes. Intrinsic causes include infection, aseptic loosening, modulus mismatch, peri-prosthetic fracture, greater trochanteric nonunion, wear synovitis, trochanteric fixation bursitis, osteolysis, and occult instability. Extrinsic causes include lumbar spine disease, tumor, peripheral vascular disease, metabolic disease, nerve injury, hernia, complex regional pain syndrome, iliopsoas impingement/tendinitis, and other gastrointestinal, genitourinary, or gynecologic diseases.

Imaging studies should include the following radiographic series for all patients: anterosuperior (AP) view of the pelvis, AP and lateral views of the hip, and AP and lateral views of the femur. Additional imaging studies are obtained based on a case-by-case evaluation and may include fluoroscopy, arthrography, nuclear imaging, ultrasound, computed tomography, and magnetic resonance imaging.⁹

Table 2. Tips and Pearls of Iliopsoas Tenotomy for Iliopsoas Impingement on Collared Femoral Prosthesis

	Description
Anatomic orientation	We advise surgeons who undertake this technique to be familiar with this area and have performed several open cases and/or endoscopic release for internal snapping hip before attempting it in a THR patient. Identification of the tendon is challenging, and scar tissue formation in the extracapsular area is expected after THR; therefore meticulous scar tissue release and fluoroscopy should be used.
Careful patient selection	Ruling out infection is the first step in evaluating a painful total hip. A complete radiographic series should be taken and evaluated for any signs of loosening, as well as malalignment of component positioning. To confirm the diagnosis, we perform an ultrasound-guided diagnostic iliopsoas injection.
Establishing portals	The first portal (anterolateral) is the only portal placed blindly. To prevent damage to neurovascular structures, we advise using fluoroscopic visualization and an over-the-guidewire technique. Additional portals are created under direct visualization, taking into consideration the neurovascular structures at risk.
Time of surgery	This is an endoscopic procedure; fluid accumulates in the surrounding soft tissue, causing swelling and reducing visualization. The longer the procedure lasts, the harder it will be to see and complete it. We suggest reducing the time of surgery as much as possible by adhering to the steps described in this article.

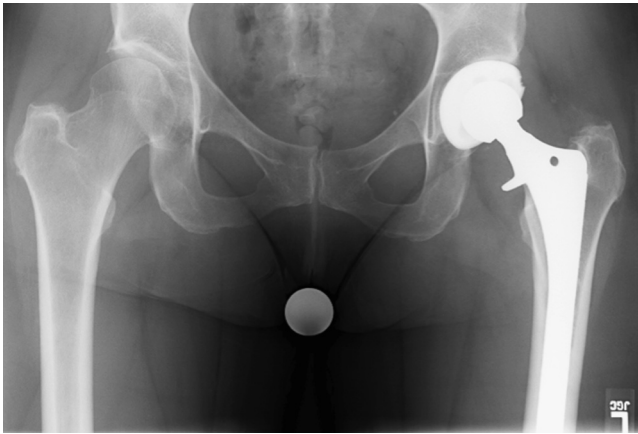


Fig 1. AP pelvis radiograph showing significant overhang of femoral collar over femoral calcar.

The majority of the causes have distinct clinical features and physical examination. However, whenever iliopsoas impingement presents with a painful THR, a complete infection workup should be performed.

The incidence of iliopsoas impingement after THR has been found to be as high as 4.3%.³ Patients usually present with groin pain that is exacerbated by hip flexion and external rotation⁵; in some cases painful anterior snapping may be present. As mentioned earlier, a plain radiograph series is obtained in all patients, followed by ultrasound, which may detect the tendon impinging over a prominent component or hardware; the examination can be performed in conjunction with diagnostic injection,¹⁰ which is helpful in establishing the diagnosis. In some cases an impinging structure is not found; in such cases, the tendon might be inflamed because of leg-length discrepancy or increased offset.

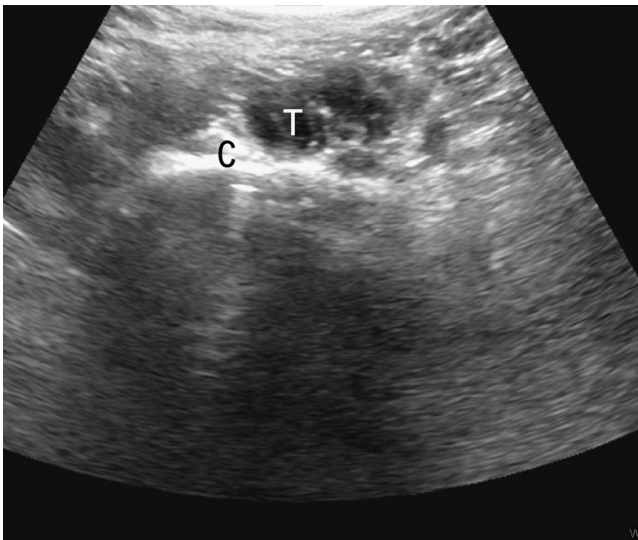


Fig 2. Ultrasound imaging showing proximity between collar (C) and iliopsoas tendon (T).

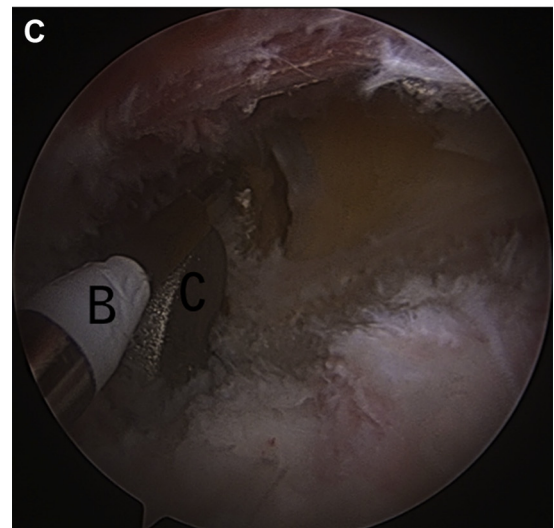
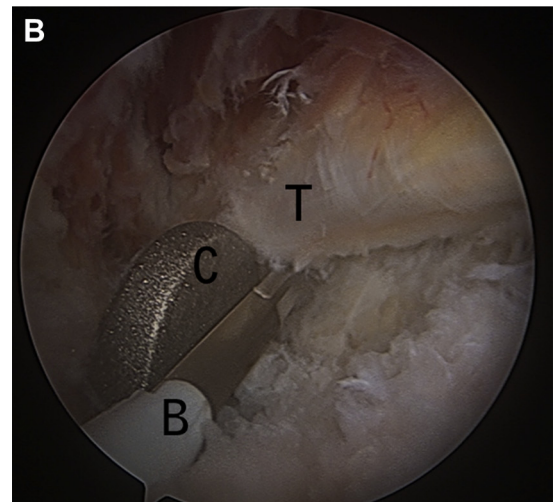
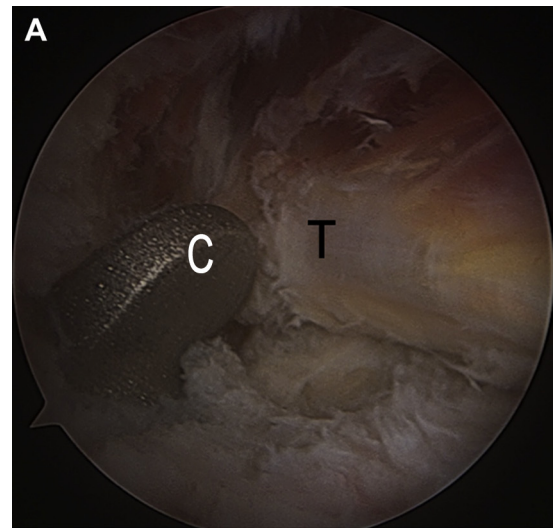


Fig 3. Endoscopic iliopsoas tenotomy. The patient is positioned in the supine position, the arthroscope is inserted through the anterolateral portal, and the beaver blade is inserted through the midanterior portal. (A) The iliopsoas tendon is rubbing on the collar. (B) Tenotomy using beaver blade. (C) After tenotomy, the tendon is no longer rubbing on the collar. (B, beaver blade; C, collar; T, iliopsoas tendon.)

Once the diagnosis has been established and the cause for the impingement has been discovered, a treatment plan should be devised. Conservative treatment is usually unsuccessful³; surgical options include tenotomy or component revision.⁹ Dora et al.,³ in a series of 30 hips, found that despite having a clear structural sight of impingement, both surgical options were successful in alleviating the symptoms.

In the native hip joint, internal snapping hip syndrome has been described when the iliopsoas tendon snaps over the iliopectineal eminence or the femoral head. The syndrome can occur in up to 10% of the general population. Surgical treatment is required only in symptomatic patients with a failure to improve despite extensive conservative measurements. Both open and endoscopic techniques have been described, both aiming at lengthening or releasing of the tendon.¹¹⁻¹⁶ The results of endoscopic iliopsoas release are as good as the open results.¹⁵⁻¹⁸ Encouraged by the good results reported with endoscopic release for internal snapping hip, similar techniques were used for iliopsoas impingement after THR. Gédouin and Hutten¹⁹ reported on 10 cases treated with endoscopic tenotomy, showing complete pain relief in 8 cases and partial pain relief in 2 cases; they concluded that endoscopic tenotomy is a safe and simple technique.

We report an iliopsoas impingement caused by an overhang of a collared stem; to our knowledge, this is only the second report in the literature of this cause of iliopsoas impingement. Brew et al.⁷ in their case report described a similar pathology that was treated with revision to a collarless stem with immediate resolution of the symptoms. Our patient had similar resolution of her symptoms after endoscopic iliopsoas tenotomy at the level of the collar.

Iliopsoas impingement on a collared stem is a rare event, but surgeons who use collared stems should be aware of this complication. Reducing the risk by checking the overhang and avoiding low neck cuts may aid in minimizing the risk. However, in the event that it does occur, an endoscopic iliopsoas tenotomy offers a less invasive treatment option when compared with component revision. Component revision involves extensive exposure, potentially damaging surrounding soft tissue, as well as blood loss, major complications, and long recovery time. In comparison, endoscopic release is a minimally invasive procedure with minimal blood loss and damage to the soft tissue and a short recovery period. Endoscopic release should be undertaken after careful patient evaluation and selection, and in some cases a component revision might be required eventually. In cases in which tendon release did not alleviate the symptoms, component revision can be undertaken without being compromised by the endoscopic release.

References

1. Postel M. Painful prosthesis. I. Possible causes. *Rev Chir Orthop Reparatrice Appar Mot* 1975;61(suppl 2):57-61 (in French).
2. Trousdale RT, Cabanela ME, Berry DJ. Anterior iliopsoas impingement after total hip arthroplasty. *J Arthroplasty* 1995;10:546-549.
3. Dora C, Houweling M, Koch P, Sierra RJ. Iliopsoas impingement after total hip replacement: The results of non-operative management, tenotomy or acetabular revision. *J Bone Joint Surg Br* 2007;89:1031-1035.
4. Taher RT, Power RA. Iliopsoas tendon dysfunction as a cause of pain after total hip arthroplasty relieved by surgical release. *J Arthroplasty* 2003;18:387-388.
5. Jasani V, Richards P, Wynn-Jones C. Pain related to the psoas muscle after total hip replacement. *J Bone Joint Surg Br* 2002;84:991-993.
6. Bricteux S, Beguin L, Fessy MH. Iliopsoas impingement in 12 patients with a total hip arthroplasty. *Rev Chir Orthop Reparatrice Appar Mot* 2001;87:820-825 (in French).
7. Brew CJ, Stockley I, Grainger AJ, Stone MH. Iliopsoas tendonitis caused by overhang of a collared femoral prosthesis. *J Arthroplasty* 2011;26:504.e17-504.e19.
8. Duffy PJ, Masri BA, Garbuz DS, Duncan CP. Evaluation of patients with pain following total hip replacement. *J Bone Joint Surg Am* 2005;87:2566-2575.
9. Lachiewicz PF, Kauk JR. Anterior iliopsoas impingement and tendinitis after total hip arthroplasty. *J Am Acad Orthop Surg* 2009;17:337-344.
10. Wank R, Miller TT, Shapiro JF. Sonographically guided injection of anesthetic for iliopsoas tendinopathy after total hip arthroplasty. *J Clin Ultrasound* 2004;32:354-357.
11. Ilizaliturri VM Jr, Villalobos FE Jr, Chaidez PA, Valero FS, Aguilera JM. Internal snapping hip syndrome: Treatment by endoscopic release of the iliopsoas tendon. *Arthroscopy* 2005;21:1375-1380.
12. Wettstein M, Jung J, Dienst M. Arthroscopic psoas tenotomy. *Arthroscopy* 2006;22:907.e1-907.e4.
13. Flannum ME, Keene JS, Blankenbaker DG, Desmet AA. Arthroscopic treatment of the painful "internal" snapping hip: Results of a new endoscopic technique and imaging protocol. *Am J Sports Med* 2007;35:770-779.
14. Byrd JW. Evaluation and management of the snapping iliopsoas tendon. *Instr Course Lect* 2006;55:347-355.
15. Dobbs MB, Gordon JE, Luhmann SJ, Szymanski DA, Schoenecker PL. Surgical correction of the snapping iliopsoas tendon in adolescents. *J Bone Joint Surg Am* 2002;84:420-424.
16. Jacobson T, Allen WC. Surgical correction of the snapping iliopsoas tendon. *Am J Sports Med* 1990;18:470-474.
17. Fabricant PD, Bedi A, De La Torre K, Kelly BT. Clinical outcomes after arthroscopic psoas lengthening: The effect of femoral version. *Arthroscopy* 2012;28:965-971.
18. Ilizaliturri VM Jr, Camacho-Galindo J. Endoscopic treatment of snapping hips, iliotibial band, and iliopsoas tendon. *Sports Med Arthrosc* 2010;18:120-127.
19. Gédouin JE, Hutten D. Technique and results of endoscopic tenotomy in iliopsoas muscle tendinopathy secondary to total hip replacement: A series of 10 cases. *Orthop Traumatol Surg Res* 2012;98(suppl):S19-S25.