

# The American Journal of Sports Medicine

<http://ajs.sagepub.com/>

---

## Does the Femoral Cam Lesion Regrow After Osteoplasty for Femoroacetabular Impingement?: Two-Year Follow-up

Asheesh Gupta, John M. Redmond, Christine E. Stake, Nathan A. Finch, Kevin F. Dunne and Benjamin G. Domb  
*Am J Sports Med* 2014 42: 2149 originally published online July 23, 2014  
DOI: 10.1177/0363546514541782

The online version of this article can be found at:

<http://ajs.sagepub.com/content/42/9/2149>

---

Published by:



<http://www.sagepublications.com>

On behalf of:

American Orthopaedic Society for Sports Medicine



Additional services and information for *The American Journal of Sports Medicine* can be found at:

**Email Alerts:** <http://ajs.sagepub.com/cgi/alerts>

**Subscriptions:** <http://ajs.sagepub.com/subscriptions>

**Reprints:** <http://www.sagepub.com/journalsReprints.nav>

**Permissions:** <http://www.sagepub.com/journalsPermissions.nav>

>> [Version of Record](#) - Aug 28, 2014

[OnlineFirst Version of Record](#) - Jul 23, 2014

[What is This?](#)

# Does the Femoral Cam Lesion Regrow After Osteoplasty for Femoroacetabular Impingement?

## Two-Year Follow-up

Asheesh Gupta,\* MD, John M. Redmond,\* MD, Christine E. Stake,\* MA, Nathan A. Finch,\* MA, Kevin F. Dunne,\* BS, and Benjamin G. Domb,\*<sup>†‡§</sup> MD  
Investigation performed at American Hip Institute, Westmont, Illinois, USA

**Background:** There are currently no studies that have examined the recurrence of the cam lesion after femoral neck osteoplasty for femoroacetabular impingement. Although patient-reported outcome (PRO) scores at midterm follow-up have shown continued success, the maintenance of a normalized alpha angle has not been shown radiographically.

**Purpose:** To assess the radiographic recurrence of cam deformity at 2-year follow-up after adequate decompression during the index hip arthroscopic procedure and correlate the findings with PRO scores. The hypothesis was that there would be no recurrence or regrowth of the cam deformity at the 2-year postoperative time point after adequate cam decompression during hip arthroscopic surgery.

**Study Design:** Case series; Level of evidence, 4.

**Methods:** Between March 2009 and January 2011, data were prospectively collected on all patients undergoing hip arthroscopic surgery with femoral neck osteoplasty. Minimum follow-up was 2 years, with radiographic images for review.

**Results:** A total of 47 patients met the inclusion criteria. The mean age of the participants at the start of the study was 37.18 years (range, 31.70-47.43 years). There were 28 men (59.57%) and 19 women (40.43%). The mean follow-up duration was 28.32 months (range, 24-41 months). The mean preoperative alpha angle (Dunn view) was 70° (range, 60°-97°), compared with 42.79° (range, 32°-50°) at 2 weeks postoperatively ( $P < .0001$ ). The mean 2-year alpha angle was 42.72° (range, 32°-54°), which was not significantly different compared with the mean 2-week alpha angle ( $P = .93$ ). Additionally, the mean femoral offset measurement was 3.7 mm (range, 0-9.9 mm) preoperatively and 7.8 mm (range, 0.3-13.9 mm) 2 weeks postoperatively ( $P < .0001$ ). The mean 2-year postoperative femoral offset measurement was 8.0 mm (range, 2.4-12.8 mm), which was not significantly different compared with the mean 2-week femoral offset measurement ( $P = .63$ ). All PRO scores were significantly improved at 3 months compared with preoperative scores and, except for visual analog scale score, continued to show improvement at 2-year follow-up.

**Conclusion:** There was no recurrence of cam deformity at 2 years after femoral neck osteoplasty for femoroacetabular impingement. PRO scores were improved at the 3-month and 2-year postoperative time points.

**Keywords:** hip arthroscopic surgery; cam; femorooplasty; hip impingement

<sup>§</sup>Address correspondence to Benjamin G. Domb, MD, Hinsdale Orthopaedics, 1010 Executive Court, Suite 250, Westmont, IL 60559, USA (e-mail: DrDomb@AmericanHipInstitute.org).

\*American Hip Institute, Westmont, Illinois, USA.

<sup>†</sup>Hinsdale Orthopaedics, Westmont, Illinois, USA.

<sup>‡</sup>Loyola University Chicago Stritch School of Medicine, Maywood, Illinois, USA.

One or more of the authors has declared the following potential conflict of interest or source of funding: B.G.D. is a consultant and receives research support from American Hip Institute, Arthrex Inc, MAKO Surgical Corporation, Breg, ATI, Pacira, and MedWest; holds stock in Stryker and MAKO Surgical Corporation; and receives royalties from Orthomerica and DJO Global.

The morphologic characteristics of femoroacetabular impingement (FAI) were first characterized in 1936 by Smith-Petersen<sup>38</sup> in the setting of old slipped capital femoral epiphysis. With further study, the concept of FAI was defined to encompass excessive abutment of the femoral head-neck junction against the acetabular rim, leading to intra-articular cartilage delamination, labral injury, and early progression of arthritis.<sup>1,4,18,42</sup> Our understanding of this disorder was further enhanced by the development of open surgical hip dislocation techniques described shortly thereafter in 2001.<sup>31</sup> Open operative management has included surgical dislocation along with femoral head osteoplasty; acetabular chondral and labral lesions are usually addressed at the same time.<sup>16</sup>

Alternatively, arthroscopic procedures to treat FAI have also gained popularity.<sup>2,7,17,34,36</sup> With regard to FAI, morphologic deformities may be either on the acetabular side (pincer impingement) or the femoral side (cam impingement), or both.<sup>25</sup> Cam lesions result from asphericity of the femoral head-neck junction, commonly located on the anterior-superior region. The contact of the cam lesion with the acetabular rim causes abrasion of the articular cartilage in the anterosuperior region of the acetabulum, with eventual tearing of the labrum in this region.<sup>11,26</sup> Arthroscopic decompression of the cam lesion results in improvement of the radiographic alpha angle and normalization of internal rotation in impingement-related disease of the hip.<sup>22</sup> Early skeptics of hip arthroscopic surgery were wary of the recurrence of the cam deformity. These concerns may have arisen after studies performed on the knee after anterior cruciate ligament reconstruction showing a thin layer of cortical bone forming over the femoral notchplasty site within 6 months of surgery.<sup>29</sup> Overgrowth of the notchplasty site by fibrocartilage has also been shown, resulting in graft impingement causing persistent effusion or lack of full extension.<sup>5</sup> Although numerous studies have shown improvement in patient-reported outcome (PRO) scores with arthroscopic surgery, there is a subgroup of patients who experience persistent or recurrent symptoms postoperatively.<sup>9,24,41</sup> Revision hip arthroscopic surgery has been performed primarily for the treatment of residual impingement deformity after index surgery.<sup>19,35</sup> To our knowledge, no study has examined the possibility of recurrence of the cam lesion after adequate decompression during the index hip arthroscopic procedure.

The aim of this study was to assess the radiographic recurrence of cam deformity at 2-year follow-up after adequate decompression during the index hip arthroscopic procedure and to correlate this with PRO scores. Our hypothesis was that there would be no recurrence or regrowth of the cam deformity at the 2-year postoperative time point after adequate cam decompression during hip arthroscopic surgery.

## MATERIALS AND METHODS

### Patient Inclusion and Data Collection

We prospectively evaluated all patients at our institution who underwent hip arthroscopic surgery with a femoral neck osteoplasty for cam resection from March 2009 to January 2011 by the senior surgeon (B.G.D.). Inclusion criteria were a preoperative alpha angle  $>60^\circ$  and a 2-week postoperative alpha angle  $<50^\circ$  on the basis of radiographic examination on the Dunn view. Minimum follow-up was 2 years, with radiographic images for review. Specifically, all patients who had radiographic images available for measurement preoperatively, 2 weeks postoperatively, or 2 years postoperatively were included (Table 1). All patients at our institution undergo 2-week and 2-year postoperative radiography. Those who were lost to follow-up were excluded. Institutional review board approval was obtained.

TABLE 1  
Inclusion and Exclusion Criteria<sup>a</sup>

Inclusion Criteria	Exclusion Criteria
Preoperative alpha angle $>60^\circ$	Lack of Dunn profile radiographs at any time point measured
Postoperative alpha angle $<50^\circ$ at 2 weeks	No 2-year follow-up
Femorooplasty performed	
2-year follow-up	

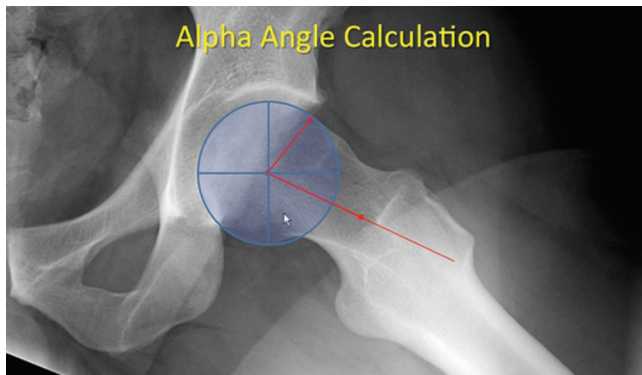
<sup>a</sup>The time points measured were the preoperative visit, 2 weeks postoperative, and 2 years postoperative.

### Physical Examination

Detailed physical examinations were conducted on all hips before surgery, including assessment of passive range of motion and measurements of flexion, abduction, and internal and external rotation. Internal and external rotation was measured while the patient was in the supine position with both the hip and knee flexed at  $90^\circ$ . Anterior impingement test results were considered positive if pain was elicited in forced flexion combined with internal rotation of the hip, as previously described by Byrd.<sup>8</sup> Lateral impingement test results were considered positive if symptoms were produced in forced abduction with external rotation. Posterior impingement test results were considered positive if pain was elicited with the hip passively extended by hanging over the examination table and then externally rotating the leg with the opposite limb in the neutral position. Evaluation of internal snapping of the iliopsoas tendon was performed as the hip was brought from a flexed, abducted, and externally rotated position into extension with internal rotation.<sup>8</sup> All physical examinations were performed and documented in degrees by the senior surgeon in a clinical setting.

### Imaging

Plain radiographs included an anteroposterior pelvic view, a Dunn view, a cross-table lateral view, and a false profile view.<sup>14,30,40</sup> Measurements were made from these views, including the Tönnis angle (acetabular inclination angle) using the method described in Jessel et al,<sup>21</sup> the lateral center edge angle of Wiberg,<sup>44</sup> joint space at its lowest point,<sup>40</sup> ischial prominence size in millimeters,<sup>43</sup> the crossover sign,<sup>20,37,43</sup> the alpha angle (Dunn view),<sup>3</sup> and offset in millimeters.<sup>15</sup> The Dunn view has been shown to best show the femoral neck/head contour.<sup>30</sup> In our practice, we flex the symptomatic hip to  $90^\circ$  and abduct  $20^\circ$  while maintaining a position of neutral rotation. The beam is directed at a point midway between the anterior superior iliac spine and the pubic symphysis. The x-ray tube-to-film distance is approximately 102 cm in a line directed perpendicular to the table. The alpha angle was measured on the Dunn view using the method described by Notzli for magnetic resonance imaging and modified by Meyer<sup>14,30,32</sup> (Figure 1). Radiographic cam impingement was defined as an alpha angle  $>60^\circ$ . Hips were classified as having pincer



**Figure 1.** Alpha angle calculation.

impingement if they had a crossover sign, coxa profunda, or protrusion acetabula. The crossover sign size was quantified according to its percentage from the superior edge of the acetabulum; for instance, crossover at the middle of the acetabulum was quantified at 50%. The same orthopaedic surgeon (B.G.D.) made all measurements using a picture archiving and communication system. All radiographs were evaluated for arthritis and graded with Tönnis classification of osteoarthritis.<sup>40</sup> Magnetic resonance imaging was performed in all patients to evaluate for labral and articular cartilage injuries. Acetabular cartilage damage and labral tears were classified intraoperatively. Cartilage damage was classified according to the Outerbridge grading and acetabular labrum articular disruption classification systems.<sup>33</sup>

### Surgical Procedure

All hip arthroscopic procedures were performed at a tertiary referral center dedicated to hip arthroscopic surgery and preservation. All were performed in the modified supine position using a minimum of 2 portals (anterolateral and midanterior).<sup>6,23</sup> The indications for surgery were labral tears with mechanical symptoms and failure of nonoperative treatment.

Intraoperative data were documented, including ligamentum teres, capsule, gluteus medius, femoral neck, acetabular rim, the presence and size of labral tears, and the presence and location of articular cartilage lesions. The Outerbridge and acetabular labrum articular disruption classifications were used to classify articular cartilage damage.<sup>33</sup>

Bony pathologic lesions were corrected under fluoroscopic guidance. An acetabuloplasty was performed for pincer impingement, and a femoral neck osteoplasty was performed for cam impingement. Labral tears were repaired when possible; otherwise, they were selectively debrided until a stable labrum was achieved while preserving as much labrum as possible. Full-thickness cartilage damage was treated with debridement to create stable borders. Microfracture was performed at the surgeon's discretion according to the technique by Crawford et al<sup>12</sup> in cases in which bone was present after the bony decompression.

### Surgical Outcomes Measure

All patients undergoing hip arthroscopic surgery were assessed with 4 PRO scores, including the modified Harris Hip Score, the Non-Arthritic Hip Score,<sup>10</sup> the Hip Outcome Score—Activities of Daily Living, and the Hip Outcome Score—Sport-Specific Subscale. These scores were collected preoperatively and at 3-month and 2-year follow-up. We elected to use all 4 questionnaires because it has been reported that there is no conclusive evidence for the use of a single PRO questionnaire for patients undergoing hip arthroscopic surgery.<sup>27,39</sup> Pain was estimated on a visual analog scale (VAS) ranging from 0 to 10 (10 being the worst), and satisfaction with surgery was rated on a scale ranging from 0 to 10.

### Statistical Analysis

An a priori analysis was performed, and it was estimated that a clinically significant difference between alpha angles preoperatively and postoperatively was 23.2°, with an SD of the preoperative group of 12.4°.<sup>13</sup> To obtain power of 0.80 or higher, we required a minimum of 12 hips in our study group (Cohen *d* = 1.909). A 2-tailed paired *t* test was used to assess differences between preoperative and postoperative scores. A dependent *t* test was used to compare the mean change in PRO score (change from preoperative to postoperative score). *P* values < .05 were considered significant. Statistical analysis was done with Microsoft Excel 2007 (Microsoft Corp) and IBM SPSS 12.0 for Windows (SPSS Inc).

## RESULTS

### Demographics

A total of 47 patients met the inclusion criteria. The average age of the study group was 37.18 years (range, 31.7–47.43 years) at the time of surgery. There were 28 men (59.57%) and 19 women (40.43%). The mean follow-up period was 28.32 months. All other demographics are presented in Table 2. At latest follow-up, all 47 patients were available.

### Physical Examination Findings

Physical examination findings are presented in Table 3. Almost every patient had a positive anterior impingement sign (*n* = 45 [95.7%]), and some patients had a positive lateral impingement sign (*n* = 29 [61.7%]), with a posterior impingement sign as well (*n* = 17 [36.17%]).

### Preoperative Imaging Findings

On radiographic examination, the mean joint space was 3.58 mm (range, 2 to 5.5 mm). The mean center edge angle was 30.16° (range, 16° to 55°). The mean crossover percentage was 15.51% (range, 0% to 50%), and the mean acetabular inclination was 5.61° (range, –11° to 23°) (Table 4).



TABLE 2  
Patient Demographics<sup>a</sup>

Variable	Value
Age, y	37.18 (31.7-47.43)
Men, No. (%)	28 (59.57)
Right side, No. (%)	28 (59.57)
Workers' compensation, No. (%)	7 (14.89)
Duration of symptoms, mo	100 (2-482)
Acute injury, No. (%)	17 (36.17)
Height, total, inches	68.77 (63-74)
Weight, lb	171.63 (102-260)
BMI, kg/m <sup>2</sup>	26.1 (18.1-33.4)

<sup>a</sup>Values are expressed as mean (range) unless otherwise indicated. BMI, body mass index.

TABLE 3  
Physical Examination Findings

Variable	Value
Anterior impingement, No. (%)	45 (95.7)
Lateral impingement, No. (%)	29 (61.7)
Posterior impingement, No. (%)	17 (36.17)
Internal hip click, No. (%)	7 (14.89)
Internal rotation, deg	20.96 (0-50)
External rotation, deg	52.45 (15-90)
Abduction, deg	43.15 (20-60)
Flexion, deg	122.77 (90-150)

<sup>a</sup>Values are expressed as mean (range) unless otherwise indicated.

## Operative Findings and Procedures

The main surgical procedures performed are summarized in Table 5. All patients underwent resection of cam with femoral neck osteoplasty for this study (n = 47 [100%]). Thirty-six patients underwent concomitant acetabuloplasty (76.6%), 37 underwent capsular release (78.7%), and 26 (55.32%) underwent labral repair.

## Comparison of Alpha Angles and Femoral Offset on Dunn View

The mean alpha angle as measured on the Dunn radiographic view was 70° (range, 60°-97°) preoperatively, compared with 42.79° (range, 32°-50°) at 2-week follow-up ( $P < .0001$ ) (Table 6). The mean 2-year alpha angle was 42.72° (range, 32°-54°), which was not significantly different compared with the mean 2-week alpha angle ( $P = .93$ ). When evaluating femoral offset, the mean value preoperatively was 3.7 mm (range, 0-9.9 mm). The mean 2-week postoperative femoral offset measurement was 7.8 mm (range, 0.3-13.9 mm), which was significantly different ( $P < .0001$ ). The mean 2-year postoperative femoral offset measurement was 8.0 mm (range, 2.4-12.8 mm), which was not significantly different compared with the mean 2-week femoral offset measurement ( $P = .63$ ).

TABLE 4  
Preoperative Radiographic Findings

Variable	Mean (range)
Joint space, mm	3.58 (2 to 5.5)
Crossover, %	15.51 (0 to 50)
Acetabular inclination, deg	5.61 (-11 to 23)
Center edge angle, deg	30.16 (16 to 55)

TABLE 5  
Surgical Procedures Performed

Arthroscopic Procedure	No. (%)
Femoral osteoplasty	47 (100)
Capsular release	37 (78.7)
Acetabuloplasty	36 (76.6)
Labral repair	26 (55.32)
Ligamentum teres debridement	23 (48.94)
Labral debridement	19 (40.43)
Chondroplasty of acetabulum	14 (29.79)
Synovectomy	12 (25.53)
Capsular repair	10 (21.28)
Removal of loose body	10 (21.28)
Chondroplasty of femoral head	9 (19.15)
Iliopsoas release	8 (17.02)
Microfracture of acetabulum	8 (17.02)
Labral reconstruction	2 (4.26)
Trochanteric bursectomy	2 (4.26)
Notchplasty	1 (2.13)
Microfracture of femoral head	1 (2.13)
Removal of os acetabuli	1 (2.13)

## Clinical Results

The mean preoperative hip-specific scores are shown in Figure 2. At the 3-month postoperative visit, all PRO scores and VAS score were significantly improved compared with preoperative scores ( $P < .05$ ). When comparing 3-month with 2-year postoperative scores, there was no significant difference in all scores ( $P > .05$ ), except for VAS score, which changed from 2.79 to 2.85 ( $P < .01$ ). The modified Harris Hip Score improved from 58.43 preoperatively to 78.92 and 79.55 postoperatively at the 3-month and 2-year time points, respectively (Figure 2A). The Hip Outcome Score—Activities of Daily Living improved from 61.15 preoperatively to 80.48 and 80.65 postoperatively for the 3-month and 2-year time points (Figure 2B). The Hip Outcome Score—Sport-Specific Subscale improved from 37.38 preoperatively to 61.84 and 62.54 postoperatively for the 3-month and 2-year time points (Figure 2C). The Non-Arthritic Hip Score improved from 54.38 preoperatively to 78.47 and 78.70 postoperatively at the 3-month and 2-year time points (Figure 2D). The VAS score improved from 5.85 preoperatively to 2.79 at the 3-month postoperative visit. Interestingly, VAS score regressed to 2.85 at the 2-year time point, which was significant ( $P < .001$ ) (Figure 2E). Last, patient satisfaction score improved from 7.85 to 7.91 from 3-month to 2-year follow-up postoperatively.

TABLE 6  
Preoperative, 2-Week Postoperative, and 2-Year Postoperative Alpha Angles and Femoral Offset Measurements

Measurement	Preoperative	2-Week Postoperative	P Value <sup>a</sup>	2-Year Postoperative	P Value <sup>b</sup>
Alpha angle, deg	70 (60-97)	42.79 (32-50)	<.0001 <sup>c</sup>	42.72 (32-54)	.93
Femoral offset, mm	3.7 (0-9.9)	7.8 (0.3-13.9)	<.0001 <sup>c</sup>	8.0 (2.4-12.8)	.63

<sup>a</sup>Preoperative versus 2-week postoperative outcomes.

<sup>b</sup>Two-week postoperative versus 2-year postoperative outcomes.

<sup>c</sup>Statistically significant ( $P < .05$ ).

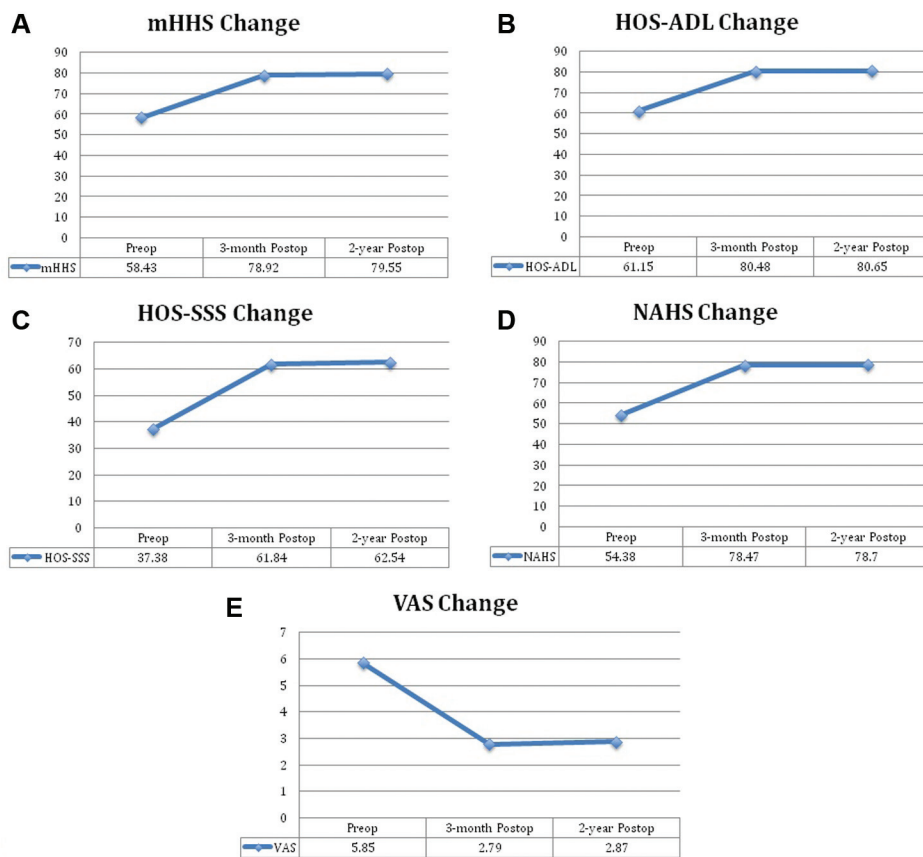


Figure 2. Patient-reported outcome scores and pain scores for patients undergoing hip arthroscopic surgery with femoral neck osteoplasty: (A) modified Harris Hip Score (mHHS), (B) Hip Outcome Score–Activities of Daily Living (HOS-ADL), (C) Hip Outcome Score–Sport-Specific Subscale (HOS-SSS), (D) Non-Arthritic Hip Score (NAHS), and (E) visual analog scale (VAS) score.

DISCUSSION

To our knowledge this is the first study assessing the radiographic recurrence of cam deformity at minimum 2-year follow-up. The results of our study offer new insights that there is no regrowth or recurrence of the cam deformity after femoral neck osteoplasty. We did show initial resection of the cam deformity on the basis of radiographic measurements 2-week postoperatively. These results are also validated by our PRO scores, which show statistically significant improvements for all scores at 3-month follow-up.

With the advent of improved arthroscopic techniques for FAI, the treatment of cam and pincer lesions has been shown to provide reproducible and successful outcomes.<sup>2,41</sup> Femoral neck osteoplasty is not without its inherent risks. Mardones et al<sup>28</sup> concluded that resection of up to 30% of the anterolateral quadrant of the head-neck junction did not significantly alter the load-bearing capacity of the proximal part of the femur. They did find a significantly decreased amount of energy required to produce a fracture with a 30% resection. Wijdicks et al<sup>45</sup> also concluded that grade II (4.0-mm) and grade III (6.0-mm) cortical notching

with cam resection resulted in significant decreases in ultimate load and energy to failure compared with the intact group. In our study group, we did not report any iatrogenic femoral neck fractures during our 2-year follow-up period.

Incomplete resection of bony impingement can result in continued postoperative signs of FAI with poor patient-related outcomes. Heyworth et al<sup>19</sup> showed that 79% of revision hip arthroscopic procedures in their study had unaddressed or undertreated bony impingement lesions. Philippon et al<sup>35</sup> published a case series on revision hip arthroscopic surgery showing that 36 of 37 patients had radiographic evidence of FAI. It must be noted that in both studies, there was no evidence of cam recurrence. The underlying pathology was not completely addressed during the primary procedure. In our study, we confirmed bony decompression of the femoral cam lesion at 2 weeks postoperatively and did not find any evidence of inadequate decompression.

Although we were able to determine that the adequately decompressed cam lesion does not reconstitute after femoral neck osteoplasty at the 2-year postoperative time point, there were certain limitations to our study. We present short-term follow-up, and it might be necessary to follow these patients at further time points to evaluate for recurrence of the cam deformity. Additionally, it is difficult to standardize patient positioning during the various radiographic views, which could possibly have led to errors in radiographic measurements. Finally, this study did not address whether patients who have residual cam lesions after decompression may have further regrowth after surgery. Another interesting area of study is the formation of cam deformity in younger patients with open physes to see if the deformity recurs with a continued high level of activity in the skeletally immature.

## CONCLUSION

In our study, we found that the cam deformity does not recur at 2-year follow-up after adequate femoral neck osteoplasty for FAI. These results show that surgeons performing hip arthroscopic surgery for FAI can address the femoral neck cam deformity with osteoplasty with confidence of continued decompression of the bony lesion at 2 years if the initial decompression is adequate.

## REFERENCES

- Anderson LA, Peters CL, Park BB, Stoddard GJ, Erickson JA, Crim JR. Acetabular cartilage delamination in femoroacetabular impingement. Risk factors and magnetic resonance imaging diagnosis. *J Bone Joint Surg Am*. 2009;91:305-313.
- Bardakos NV, Vasconcelos JC, Villar RN. Early outcome of hip arthroscopy for femoroacetabular impingement: the role of femoral osteoplasty in symptomatic improvement. *J Bone Joint Surg Br*. 2008;90:1570-1575.
- Barton C, Salineros MJ, Rakhra KS, Beaulé PE. Validity of the alpha angle measurement on plain radiographs in the evaluation of cam-type femoroacetabular impingement. *Clin Orthop Relat Res*. 2011;469:464-469.
- Beck M, Kalhor M, Leunig M, Ganz R. Hip morphology influences the pattern of damage to the acetabular cartilage: femoroacetabular impingement as a cause of early osteoarthritis of the hip. *J Bone Joint Surg Br*. 2005;87:1012-1018.
- Bents RT, Jones RC, May DA, Snearly WS. Intercondylar notch encroachment following anterior cruciate ligament reconstruction: a prospective study. *Am J Knee Surg*. 1998;11:81-88.
- Byrd JW. Hip arthroscopy. The supine position. *Clin Sports Med*. 2001;20:703-731.
- Byrd JW. The role of hip arthroscopy in the athletic hip. *Clin Sports Med*. 2006;25:255-278.
- Byrd JW. Evaluation of the hip: history and physical examination. *North Am J Sports Phys Ther*. 2007;2:231-240.
- Byrd JW, Jones KS. Prospective analysis of hip arthroscopy with 2-year follow-up. *Arthroscopy*. 2000;16:578-587.
- Christensen CP, Althausen PL, Mittleman MA, Lee JA, McCarthy JC. The nonarthritic hip score: reliable and validated. *Clin Orthop Relat Res*. 2003;406:75-83.
- Clohisey JC, Knaus ER, Hunt DM, Leshner JM, Harris-Hayes M, Prather H. Clinical presentation of patients with symptomatic anterior hip impingement. *Clin Orthop Relat Res*. 2009;467:638-644.
- Crawford K, Philippon MJ, Sekiya JK, Rodkey WG, Steadman JR. Microfracture of the hip in athletes. *Clin Sports Med*. 2006;25:327-335.
- Domb BG, Finley ZJ, Baise RA, Botser IB. Osteoplasty for cam type impingement is more accurate when performed open than arthroscopic (SS-41). *Arthroscopy*. 2012;28:e23.
- Dunn DM. Anteversion of the neck of the femur; a method of measurement. *J Bone Joint Surg Br*. 1952;34:181-186.
- Eijer H, Mohamed N, Ganz R. Cross-table lateral radiographs for screening of anterior femoral head-neck offset in patients with femoroacetabular impingement. *Hip Int*. 2001;11:37-41.
- Ganz R, Gill TJ, Gautier E, Ganz K, Krugel N, Berlemann U. Surgical dislocation of the adult hip a technique with full access to the femoral head and acetabulum without the risk of avascular necrosis. *J Bone Joint Surg Br*. 2001;83:1119-1124.
- Guanche CA, Bare AA. Arthroscopic treatment of femoroacetabular impingement. *Arthroscopy*. 2006;22:95-106.
- Harris WH. Etiology of osteoarthritis of the hip. *Clin Orthop Relat Res*. 1986;213:20-33.
- Heyworth BE, Shindle MK, Voos JE, Rudzki JR, Kelly BT. Radiologic and intraoperative findings in revision hip arthroscopy. *Arthroscopy*. 2007;23:1295-1302.
- Jamali AA, Mladenov K, Meyer DC, Martinez A, Beck M, Ganz R, Leunig M. Anteroposterior pelvic radiographs to assess acetabular retroversion: high validity of the "cross-over-sign." *J Orthop Res*. 2007;25:758-765.
- Jessel RH, Zurakowski D, Zilkens C, Burstein D, Gray ML, Kim YJ. Radiographic and patient factors associated with pre-radiographic osteoarthritis in hip dysplasia. *J Bone Joint Surg Am*. 2009;91:1120-1129.
- Kelly BT, Bedi A, Robertson CM, Dela Torre K, Giveans MR, Larson CM. Alterations in internal rotation and alpha angles are associated with arthroscopic cam decompression in the hip. *Am J Sports Med*. 2012;40:1107-1112.
- Kelly BT, Weiland DE, Schenker ML, Philippon MJ. Arthroscopic labral repair in the hip: surgical technique and review of the literature. *Arthroscopy*. 2005;21:1496-1504.
- Laude F, Sariali E. [Treatment of FAI via a minimally invasive ventral approach with arthroscopic assistance. Technique and midterm results]. *Der Orthopade*. 2009;38:419-428.
- Lavigne M, Parvizi J, Beck M, Siebenrock KA, Ganz R, Leunig M. Anterior femoroacetabular impingement: part I. Techniques of joint preserving surgery. *Clin Orthop Relat Res*. 2004;418:61-66.
- Leunig M, Beaulé PE, Ganz R. The concept of femoroacetabular impingement: current status and future perspectives. *Clin Orthop Relat Res*. 2009;467:616-622.
- Lodhia P, Slobogean GP, Noonan VK, Gilbert MK. Patient-reported outcome instruments for femoroacetabular impingement and hip labral pathology: a systematic review of the clinimetric evidence. *Arthroscopy*. 2011;27:279-286.

28. Mardones RM, Gonzalez C, Chen Q, Zobitz M, Kaufman KR, Trousdale RT. Surgical treatment of femoroacetabular impingement: evaluation of the effect of the size of the resection. *J Bone Joint Surg Am.* 2005;87:273-279.
29. May DA, Snearly WN, Bents R, Jones R. MR imaging findings in anterior cruciate ligament reconstruction: evaluation of notchplasty. *AJR Am J Roentgenol.* 1997;169:217-222.
30. Meyer DC, Beck M, Ellis T, Ganz R, Leunig M. Comparison of six radiographic projections to assess femoral head/neck asphericity. *Clin Orthop Relat Res.* 2006;445:181-185.
31. Myers SR, Eijer H, Ganz R. Anterior femoroacetabular impingement after periacetabular osteotomy. *Clin Orthop Relat Res.* 1999;363:93-99.
32. Notzli HP, Wyss TF, Stoecklin CH, Schmid MR, Treiber K, Hodler J. The contour of the femoral head-neck junction as a predictor for the risk of anterior impingement. *J Bone Joint Surg Br.* 2002;84:556-560.
33. Outerbridge R. The etiology of chondromalacia patellae 1961. *Clin Orthop Relat Res.* 2001;389:5-8.
34. Philippon MJ, Schenker ML. Arthroscopy for the treatment of femoroacetabular impingement in the athlete. *Clin Sports Med.* 2006;25:299-308.
35. Philippon MJ, Schenker ML, Briggs KK, Kuppersmith DA, Maxwell RB, Stubbs AJ. Revision hip arthroscopy. *Am J Sports Med.* 2007;35:1918-1921.
36. Sampson TG. Arthroscopic treatment of femoroacetabular impingement. *Am J Orthop.* 2008;37:608-612.
37. Siebenrock KA, Schoeniger R, Ganz R. Anterior femoro-acetabular impingement due to acetabular retroversion. Treatment with periacetabular osteotomy. *J Bone Joint Surg Am.* 2003;85:278-286.
38. Smith-Petersen MN. The classic: treatment of malum coxae senilis, old slipped upper femoral epiphysis, intrapelvic protrusion of the acetabulum, and coxa plana by means of acetabuloplasty 1936. *Clin Orthop Relat Res.* 2009;467:608-615.
39. Tijssen M, van Cingel R, van Melick N, de Visser E. Patient-reported outcome questionnaires for hip arthroscopy: a systematic review of the psychometric evidence. *BMC Musculoskel Disord.* 2011;12:117.
40. Tönnis D, Heinecke A. Acetabular and femoral anteversion: relationship with osteoarthritis of the hip. *J Bone Joint Surg Am.* 1999;81:1747-1770.
41. Trompeter A, Colegate-Stone T, Khakha R, Hull J. Hip arthroscopy for femoroacetabular impingement: results of 118 consecutive cases in a district general hospital. *Hip Int.* 2013;23:400-405.
42. Wagner S, Hofstetter W, Chiquet M, Mainil-Varlet P, Stauffer E, Ganz R, Siebenrock KA. Early osteoarthritic changes of human femoral head cartilage subsequent to femoro-acetabular impingement. *Osteoarthritis Cartilage.* 2003;11:508-518.
43. Werner CM, Copeland CE, Ruckstuhl T, Stromberg J, Turen CH, Kalberer F, Zingg PO. Radiographic markers of acetabular retroversion: correlation of the cross-over sign, ischial spine sign and posterior wall sign. *Acta Orthop Belg.* 2010;76:166-173.
44. Wiberg G. Shelf operation in congenital dysplasia of the acetabulum and in subluxation and dislocation of the hip. *J Bone Joint Surg Am.* 1953;35:65-80.
45. Wijdicks CA, Balldin BC, Jansson KS, Stull JD, Laprade RF, Philippon MJ. Cam lesion femoral osteoplasty: in vitro biomechanical evaluation of iatrogenic femoral cortical notching and risk of neck fracture. *Arthroscopy.* 2013;29:1608-1614.

---

For reprints and permission queries, please visit SAGE's Web site at <http://www.sagepub.com/journalsPermissions.nav>