

## Technical Note

# Endoscopic Repair of Proximal Hamstring Avulsion

Benjamin G. Domb, M.D., Dror Linder, M.D., Kinzie G. Sharp, M.S., P.A.-C.,  
Adam Sadik, B.S., and Michael B. Gerhardt, M.D.

**Abstract:** Hamstring muscle injuries are common in athletes and mostly consist of sprains at the myotendinous junction, which often respond well to conservative treatment. Proximal hamstring avulsion injuries, though less common, can be severely debilitating. This injury is often seen in water skiers but has been described in many other sports and in middle-aged patients. Complete avulsions in young and active individuals do not respond well to conservative treatment and may require surgical repair. In contrast, many partial tears may be treated nonoperatively. However, when symptoms continue despite a trial of extensive therapy, surgery may be warranted. Traditional surgery for proximal hamstring repair is performed with the patient in the prone position with an incision made longitudinally or along the gluteal fold, followed by identification of the torn tendons and fixation to the ischial tuberosity. We describe a novel surgical technique for endoscopic repair of proximal hamstring avulsion injuries.

The hamstring muscle group consists of the biceps femoris (long and short heads), semitendinosus, and semimembranosus muscles. Except for the short head of the biceps femoris, all 3 have their origin at the ischial tuberosity and cross 2 joints. As biarticular muscles, they are seldom stretched during daily activities and are vulnerable to eccentric loading. The hamstring muscles are among the most commonly injured muscles in athletes.<sup>1-3</sup> Most of these injuries are muscle strains at the myotendinous junction,<sup>4,5</sup> which respond to conservative treatment.<sup>6,7</sup> Injuries to the proximal hamstring origin are less common and were detected in 12% of all hamstring injuries.<sup>8</sup>

The treatment of proximal hamstring origin injuries remains controversial; however, several indications for operative treatment have been recommended including (1) osseous avulsion with 2 cm of retraction, (2) complete tears in all 3 tendons with or without

retraction, and (3) partial tears that remain symptomatic despite extensive conservative treatment.<sup>9-11</sup> The surgical technique for open proximal hamstring repair was described by Carmichael et al.<sup>12</sup> and involves a longitudinal incision, identification of the sciatic nerve and the torn tendons, and fixation of the tendons to the ischial tuberosity through the use of suture anchors.

Advances in techniques and equipment have broadened the indications and pathologies amenable for arthroscopic treatment. Accessing extra-articular structures outside the hip joint is feasible and has been previously described.<sup>13-17</sup> Advantages and challenges of endoscopic repair of proximal hamstring avulsion are presented in Table 1, and tips and pearls are shown in Table 2.

## Surgical Technique

Under general anesthesia, the patient is placed in the prone position with all bony prominences well padded and the arms placed at 90° of abduction. The right leg and buttock are prepared and draped (Fig 1). Two working portals are used, direct posterior and posterolateral, both in the gluteal fold. Additional portals may be added and used, primarily for anchor placement. The neurovascular structures at risk during portal placement are (1) the sciatic nerve, which lies lateral to the proximal hamstring origin, on average, 1.2 cm from the ischial tuberosity; (2) the posterior femoral cutaneous branch, which begins above the ischial tuberosity and travels laterally in the subcutaneous tissue and in the gluteal fold and supplies sensation to the posterior thigh; and (3) the inferior

From the American Hip Institute (B.G.D., D.L., K.G.S., A.S.), Chicago; Hinsdale Orthopaedics (B.G.D., K.G.S.), Hinsdale; Loyola University Stritch School of Medicine (B.G.D.), Chicago, Illinois; and Santa Monica Orthopaedic and Sports Medicine Group (M.B.G.), Santa Monica, California, U.S.A.

The authors report the following potential conflict of interest or source of funding in relation to this article: American Hip Institute, Adventist Hinsdale Hospital, MedWest, and Arthrex, Inc.

Received August 31, 2012; accepted October 10, 2012.

Address correspondence to Benjamin G. Domb, M.D., Hinsdale Orthopaedics, 1010 Executive Ct, Ste 250, Westmont, IL 60559, U.S.A. E-mail: DrDomb@americanhipinstitute.org

© 2013 by the Arthroscopy Association of North America

2212-6287/12577/\$36.00

<http://dx.doi.org/10.1016/j.eats.2012.10.003>

**Table 1.** Advantages and Potential Pitfalls of Endoscopic Repair of Proximal Hamstring Injuries

Technique Advantages	Potential Pitfalls
<ul style="list-style-type: none"> <li>• Minimal disruption of normal anatomy</li> <li>• Evaluation of partial-thickness tears</li> <li>• Superior visualization</li> <li>• Potentially decreased neurovascular complications because of improved visualization</li> <li>• Decreased bleeding</li> </ul>	<ul style="list-style-type: none"> <li>• Injury to neurovascular structures during blind portal placement</li> <li>• Injury to the sciatic nerve if disoriented to arthroscopic anatomy</li> <li>• Technical challenges of passing and shuttling suture for repair</li> <li>• Increased operative time, particularly during early part of learning curve</li> <li>• Steep learning curve</li> </ul>

gluteal nerve and artery, which lie deep to the gluteus maximus 5 cm proximal to the ischial tuberosity.

Under fluoroscopic visualization, the arthroscope is inserted through the posterolateral portal in the gluteal fold and into the hamstring bursa, by use of a switching stick for blunt dissection and an over-the-guidewire technique. After establishing the posterolateral portal, the surgeon accesses the posteromedial portal in the same fashion using fluoroscopic visualization and blunt dissection. Both fluoroscopy and blunt dissection are used to ensure correct instrument positioning and to help avoid damage to the sciatic nerve.

Upon establishing the 2 portals, the surgeon clears the subgluteal space of scar tissue using a shaver. This is followed by identification and protection of the sciatic nerve (Fig 2). If necessary, sciatic neurolysis can be performed, consisting of exposing the nerve and then removing fibrous bands if present. During this procedure, care is taken to avoid contacting the nerve with any instrument.

Next, the hamstring origins are inspected. The long head of the biceps femoris and the semitendinosus share a common origin, which is crescent shaped, whereas the semimembranosus has a distinct, separate origin, which is lateral and anterior to the common insertion of the latter 2 muscles. Complete tears require

identification of the torn tendon, which usually retracts distally. In contrast, for partial tears, the shaver may be used to debride the torn portions and define the tear (Fig 3) while the undamaged portions of the tendon are left intact. The footprint of the tendon attachment to the ischial tuberosity is cleared of soft tissue with the shaver, and a bed of bleeding bone is created with a 5.5-mm burr to augment healing.

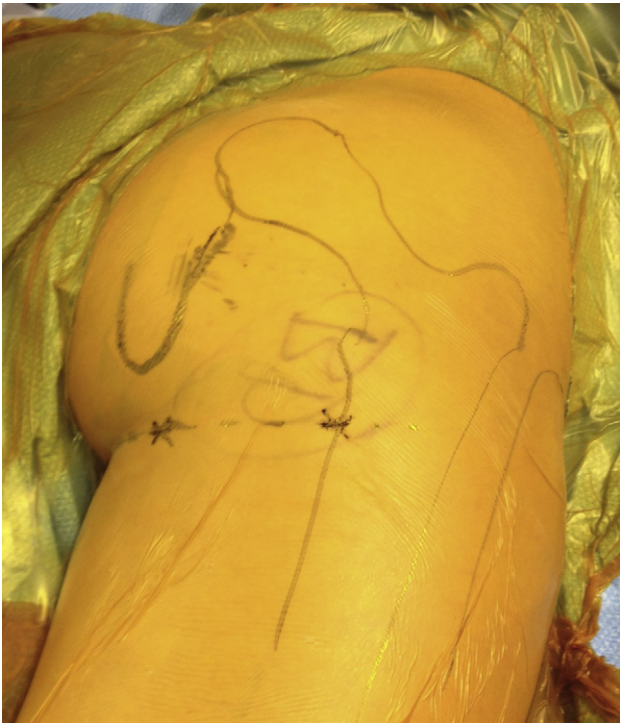
Additional portals are established for anchor placement. The portal position is determined by use of a spinal needle and fluoroscopic visualization. Through these portals, 5.5-mm polyetheretherketone Corkscrew anchors (Arthrex, Naples, FL) are placed in the footprint (Fig 4). Between 2 and 4 anchors may be used depending on the size of the tear and the size of the ischial tuberosity. Horizontal mattress sutures are passed through the tendon with a 90° lasso (Arthrex) (Fig 5). Lastly, arthroscopic suture tying is implemented to achieve fixation of the tendon to the bed of bleeding bone (Fig 6). Video 1 demonstrates the technique.

### Rehabilitation and Recovery

In acute cases or when approximation of the tendons to the ischial tuberosity does not require knee flexion, the patient is kept in a hip brace with 20 lb of weight

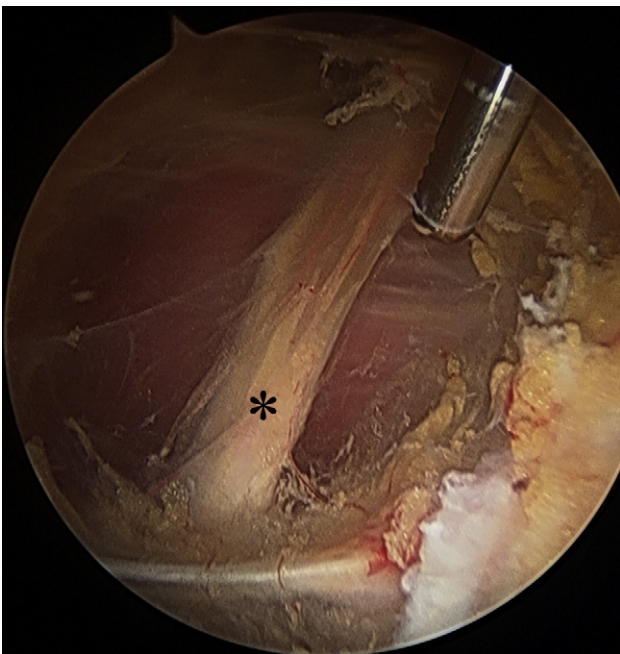
**Table 2.** Tips and Pearls of Endoscopic Repair of Proximal Hamstring Injuries

	Description
Anatomic orientation	Because the hamstring area is not encountered regularly in arthroscopic/endoscopic surgery, we advise surgeons who undertake this technique to be familiar with this area and to have performed several open cases and/or cadaveric laboratory cases before attempting an endoscopic case.
Careful patient selection	Chronic cases with extensive retraction and scarring might not be suitable for endoscopic repair, especially in the first few cases.
Patient position	The patient is placed in the prone position. The length of surgery may vary; therefore, we advise careful patient positioning and padding to avoid any complications associated with this position.
Establishing portals	The first portal (posterolateral) is the only one established blindly. To prevent damage to neurovascular structures, we advise using fluoroscopic visualization and an over-the-guidewire technique. Additional portals are created under direct visualization with the neurovascular structures at risk of being taken into consideration.
Protecting sciatic nerve	After the 2 working portals have been established and the soft tissue (hamstring bursa) has been cleared, identification of the sciatic nerve should immediately follow, with care not to touch the nerve with any instrument. Throughout the procedure, the nerve should be visualized.
Suture management	Using a cannula for suture management reduces the risk of wire mishandling or soft-tissue interposition and facilitates fast suture passing and tying.
Tendon repair	In chronic cases and middle-aged patients, tendon quality might be poor. It is imperative to perform refixation of good tendon tissue to bone and debride all the necrotic nonviable tissue.
Time of surgery	Because the procedure is endoscopic, fluid accumulates in the surrounding soft tissue, causing it to swell and reduce visualization. The longer the procedure lasts, the more difficult it will be to see and complete it. We suggest reducing the time of surgery as much as possible by adhering to the steps described in this article.

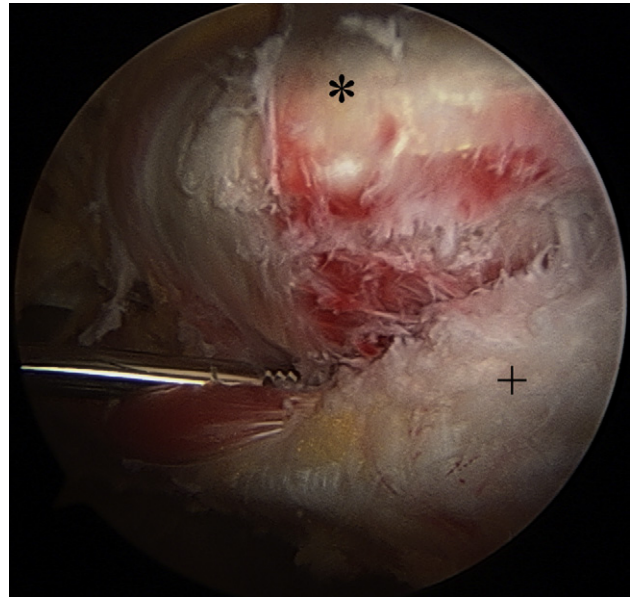


**Fig 1.** The patient is in the prone position for a right proximal hamstring endoscopic repair. Anatomic landmarks and portal positions are marked, and the patient is prepared and draped.

bearing with crutches for the first 6 weeks. The hip brace is locked at  $0^{\circ}$  to  $30^{\circ}$  for the first 3 weeks and at  $0^{\circ}$  to  $60^{\circ}$  for the subsequent 3 weeks. At 6 weeks postoperatively, the brace and crutches are discontinued, and the patient begins physical therapy.

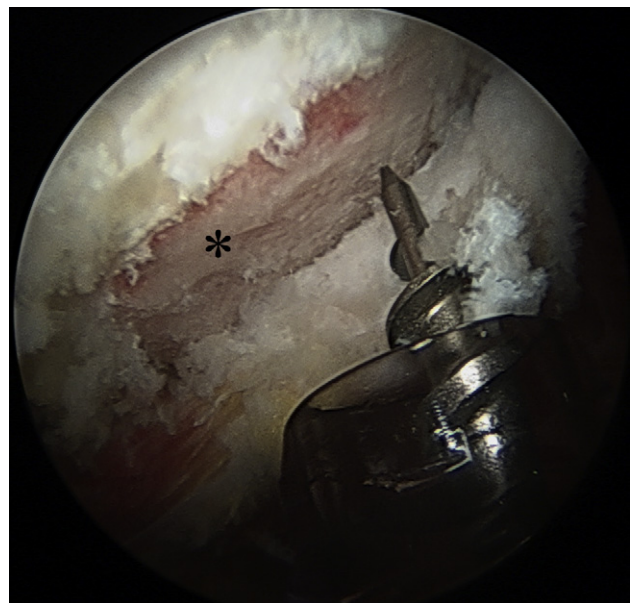


**Fig 2.** Endoscopic view from the lateral portal after hamstring bursectomy, showing identification and protection of the sciatic nerve (asterisk). The patient is in the prone position.



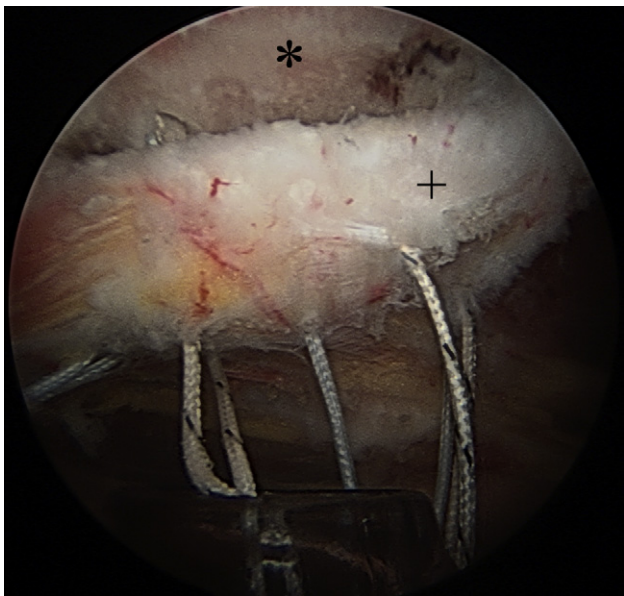
**Fig 3.** Endoscopic view from the lateral portal showing partial tear of the proximal hamstring origin. The asterisk indicates the ischial tuberosity; the plus sign indicates the hamstring tendons. The patient is in the prone position.

In chronic retracted cases when the repair is performed under tension with the knee flexed, a hinged knee brace is added to maintain the knee in flexion. The knee is then gradually brought to extension over the 6-week period.



**Fig 4.** Endoscopic view from the lateral portal showing insertion of a 5.5-mm polyetheretherketone screw (Arthrex) to the footprint of the proximal hamstring. The footprint has been cleared of soft tissue, and a bed of bleeding was created using a burr to facilitate tendon-bone healing. The asterisk indicates the ischial tuberosity. The patient is in the prone position.

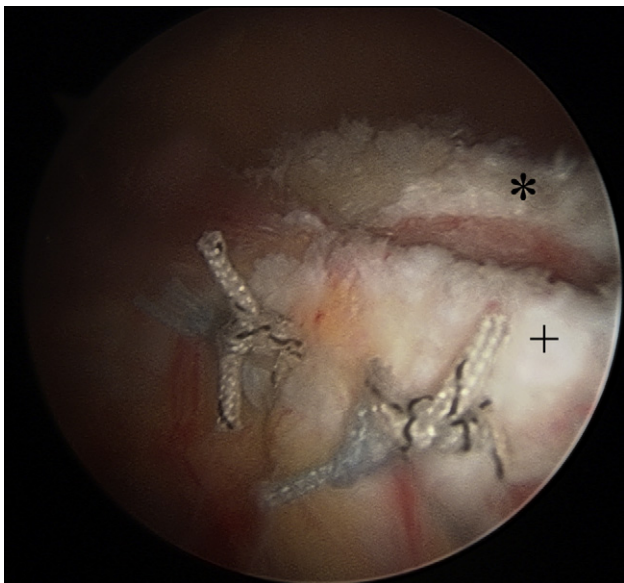




**Fig 5.** Endoscopic view from the lateral portal showing mattress sutures passed through the tendon. The asterisk indicates the ischial tuberosity; the plus sign indicates the hamstring tendons. The patient is in the prone position.

### Discussion

Hamstring injuries are common in athletes and usually occur as sprains of the myotendinous junction that respond well to conservative treatment. In a review of 46 college football players, Heiser et al.<sup>18</sup> reported a return to sport after a mean of 2 weeks after conservative treatment. In contrast, proximal hamstring avulsion is an uncommon and debilitating injury. The diagnosis of proximal hamstring avulsion is



**Fig 6.** Endoscopic view from the lateral portal showing the final repair of the proximal hamstring origin. The asterisk indicates the ischial tuberosity; the plus sign indicates the hamstring tendons. The patient is in the prone position.

usually delayed and is based on clinical history, physical examination, and imaging. Clinical history should identify the mechanism of injury, which is usually eccentric loading caused by hip flexion and forced knee extension. Patients will usually report a sharp pain and a pop or snap in the posterior proximal thigh. Swelling and hematoma of the posterior thigh will usually develop over the following 48 hours. In complete tears the physical examination shows weakness in knee flexion, a palpable gap with muscle retraction, and a positive bowstring sign.<sup>19</sup> Magnetic resonance imaging is used to confirm the diagnosis<sup>8,20,21</sup> because of the accuracy of imaging and ability to allow calculation of muscle retraction.

There are many reports in the literature describing surgical treatment for complete and incomplete avulsion of the proximal hamstring<sup>9,10,22-24</sup>; however, the indications for surgical repair have yet to be completely established. Most series reporting on surgical outcomes are small or have mixed patient cohorts including both young athletes and middle-aged non-athletes, requiring both acute and chronic repairs. We present our endoscopic technique for proximal hamstring repair. Endoscopic treatment offers a less invasive method to address proximal hamstring injuries and might decrease perioperative pain and complications. Advantages also include improved visualization of the anatomy, which may enable improved repairs as the technique is refined. We believe that endoscopic repair can be beneficial, especially in acute repairs; however, further research on the role of endoscopic proximal hamstring repair is warranted.

### References

1. Bennell KL, Crossley K. Musculoskeletal injuries in track and field: Incidence, distribution and risk factors. *Aust J Sci Med Sport* 1996;28:69-75.
2. Orchard J, Seward H. Epidemiology of injuries in the Australian Football League, seasons 1997-2000. *Br J Sports Med* 2002;36:39-44.
3. Woods C, Hawkins RD, Maltby S, Hulse M, Thomas A, Hodson A. The Football Association Medical Research Programme: An audit of injuries in professional football—Analysis of hamstring injuries. *Br J Sports Med* 2004;38:36-41.
4. Garrett WE Jr. Muscle strain injuries: Clinical and basic aspects. *Med Sci Sports Exerc* 1990;22:436-443.
5. Garrett WE Jr, Rich FR, Nikolaou PK, Vogler JB III. Computed tomography of hamstring muscle strains. *Med Sci Sports Exerc* 1989;21:506-514.
6. Agre JC. Hamstring injuries. Proposed aetiological factors, prevention, and treatment. *Sports Med* 1985;2:21-33.
7. Jarvinen TA, Jarvinen TL, Kaariainen M, Kalimo H, Jarvinen M. Muscle injuries: Biology and treatment. *Am J Sports Med* 2005;33:745-764.
8. Koulouris G, Connell D. Evaluation of the hamstring muscle complex following acute injury. *Skeletal Radiol* 2003;32:582-589.

9. Wood DG, Packham I, Trikha SP, Linklater J. Avulsion of the proximal hamstring origin. *J Bone Joint Surg Am* 2008;90:2365-2374.
10. Sarimo J, Lempainen L, Mattila K, Orava S. Complete proximal hamstring avulsions: A series of 41 patients with operative treatment. *Am J Sports Med* 2008;36:1110-1115.
11. Cohen S, Bradley J. Acute proximal hamstring rupture. *J Am Acad Orthop Surg* 2007;15:350-355.
12. Carmichael J, Packham I, Trikha SP, Wood DG. Avulsion of the proximal hamstring origin. Surgical technique. *J Bone Joint Surg Am* 2009;91:249-256.
13. Domb BG, Nasser RM, Botser IB. Partial-thickness tears of the gluteus medius: Rationale and technique for trans-tendinous endoscopic repair. *Arthroscopy* 2010;26:1697-1705.
14. Voos JE, Rudzki JR, Shindle MK, Martin H, Kelly BT. Arthroscopic anatomy and surgical techniques for peritrochanteric space disorders in the hip. *Arthroscopy* 2007;23:1246.e1-1246.e5.
15. Voos JE, Shindle MK, Pruett A, Asnis PD, Kelly BT. Endoscopic repair of gluteus medius tendon tears of the hip. *Am J Sports Med* 2009;37:743-747.
16. Larson CM, Guanche CA, Kelly BT, Clohisy JC, Ranawat AS. Advanced techniques in hip arthroscopy. *Instr Course Lect* 2009;58:423-436.
17. Kandemir U, Bharam S, Philippon MJ, Fu FH. Endoscopic treatment of calcific tendinitis of gluteus medius and minimus. *Arthroscopy* 2003;19:E4.
18. Heiser TM, Weber J, Sullivan G, Clare P, Jacobs RR. Prophylaxis and management of hamstring muscle injuries in intercollegiate football players. *Am J Sports Med* 1984;12:368-370.
19. Birmingham P, Muller M, Wickiewicz T, Cavanaugh J, Rodeo S, Warren R. Functional outcome after repair of proximal hamstring avulsions. *J Bone Joint Surg Am* 2011;93:1819-1826.
20. Linklater JM, Hamilton B, Carmichael J, Orchard J, Wood DG. Hamstring injuries: Anatomy, imaging, and intervention. *Semin Musculoskelet Radiol* 2010;14:131-161.
21. Bencardino JT, Mellado JM. Hamstring injuries of the hip. *Magn Reson Imaging Clin N Am* 2005;13:677-690.
22. Folsom GJ, Larson CM. Surgical treatment of acute versus chronic complete proximal hamstring ruptures: Results of a new allograft technique for chronic reconstructions. *Am J Sports Med* 2008;36:104-109.
23. Harris JD, Griesser MJ, Best TM, Ellis TJ. Treatment of proximal hamstring ruptures—A systematic review. *Int J Sports Med* 2011;32:490-495.
24. Klingele KE, Sallay PI. Surgical repair of complete proximal hamstring tendon rupture. *Am J Sports Med* 2002;30:742-747.