

Endoscopic Repair of Full-Thickness Gluteus Medius Tears

Benjamin G. Domb, M.D., and Dominic S. Carreira, M.D.

Abstract: Tears in the gluteus medius and minimus tendons recently have emerged as an important cause of chronic greater trochanteric pain syndrome. Increasing recognition of the gluteal insertion as a cause of chronic pain and weakness, as well as technologic advances in endoscopic hip surgery, has made gluteal insertional repair a rapidly emerging technique in minimally invasive surgery of the hip. We present an endoscopic double-row technique for gluteal insertional repair that allows for visualization, debridement, and repair, re-creating the normal footprint.

Tears in the gluteus medius and minimus tendons recently have emerged as an important cause of chronic greater trochanteric pain syndrome. Historically, pain over the greater trochanter was presumed solely to be due to bursitis, but several studies have challenged this and shown gluteus tears as a source of pain.¹ Degenerative tears occur more often than acute tears,^{2,3} and gluteus medius tears occur more often than gluteus minimus tears.^{4,5} Tears at the insertion of the gluteus medius can be intrasubstance, partial, or complete and can occur either spontaneously or traumatically.^{4,6,7} Also referred to as the “rotator cuff of the hip,” these tendons pathologically share a number of similarities to those of the shoulder. In addition to repairing the tendon(s), the associated bursitis may also be treated. Although multiple publications exist regarding the treatment of bursitis, including open bursectomy and iliotibial band lengthening or release, few have addressed gluteal insertional pathologies. Open repair techniques have included repairs using both transosseous sutures⁶ and suture anchors.⁸ Few reports have been published on the outcomes of open repairs. The collective series of studies suggests that

most patients respond favorably.⁷ A survey of French surgeons reporting the results of open repairs in 29 patients showed 12 excellent results, 6 good outcomes, and 11 poor outcomes.⁹ Endoscopic techniques have included gluteal debridement or repairs, bursectomy, and iliotibial band release.¹⁰ Voos et al.¹¹ described a technique of endoscopic repair of the gluteal insertion with complete relief of symptoms in 10 patients. The advantages and limitations of endoscopic repair of the gluteus medius are described in Table 1. In this article we present the repair of full-thickness tears with an endoscopic suture bridge technique (Video 1).

Clinical Presentation

Greater trochanteric pain syndrome typically causes dull, aching pain along the lateral aspect of the hip, occasionally radiating into the buttock or lateral thigh. Physical examination and magnetic resonance imaging (MRI) confirm the diagnosis. Tenderness to palpation at the gluteal insertion and pain with resisted hip abduction frequently are noted. In contrast to partial tears of the gluteal insertion, full-thickness tears frequently present with significant weakness in abduction. MRI typically shows peritrochanteric abnormalities, including bursal thickening and edema, and gluteal insertional tendinopathy or tearing. Blankenbaker et al.¹² showed that findings on MRI do not correlate well with symptoms. In an evaluation of 256 hips, 88% of patients with trochanteric pain had MRI abnormalities at the gluteal insertion and 50% of asymptomatic patients had similar MRI findings, thereby underscoring the importance of clinical examination in these patients. Gluteus medius tears often respond well to conservative measures, including anti-inflammatory medication, physical therapy, and steroid injections, but recalcitrant cases are candidates for surgical treatment.

From the American Hip Institute (B.G.D.), Chicago, Illinois; Hinsdale Orthopaedics (B.G.D.), Hinsdale, Illinois; Loyola University Stritch School of Medicine (B.G.D.), Chicago, Illinois; Broward Health Orthopedics (D.S.C.), Fort Lauderdale; and School of Medicine (D.S.C.), Nova Southeastern University, Davie, Florida, U.S.A.

The authors report the following potential conflict of interest or source of funding in relation to this article: Arthrex. Research support.

Received September 7, 2012; accepted November 28, 2012.

Address correspondence to Benjamin G. Domb, M.D., Hinsdale Orthopaedics, 1010 Executive Ct, Ste 250, Westmont, IL 60559, U.S.A. E-mail: DrDomb@americanhipinstitute.org

© 2013 by the Arthroscopy Association of North America

2212-6287/12595/\$36.00

<http://dx.doi.org/10.1016/j.eats.2012.11.005>

Table 1. Advantages and Limitations of Endoscopic Gluteus Medius Repair

Advantages	Limitations
Less invasive approach with minimal disruption of normal anatomy	Poor portal placement
Decreased infections	Maintenance of hemostasis for visualization
Decreased scarring/improved cosmesis	Difficulty with suture passage and management
Decreased pain	Poor anchor placement
Accelerated rehabilitation/early range of motion	

Technique

The procedure typically is performed on an outpatient basis with the patient under general anesthesia. Regional anesthesia (e.g., lumbar plexus or epidural) or local 0.5% bupivacaine may be used for postoperative pain control. The patient is placed in the supine position on the operating table. Because a diagnostic examination of the hip joint frequently is performed at the same time, the positioning equipment for hip arthroscopy is used routinely. The foot may be externally or internally rotated to bring the greater trochanter into a better field of view. The hip and knee are placed in neutral flexion/extension, and the hip is abducted 15°.

Endoscopic Approach

Standard anterolateral and midanterior arthroscopic portals for hip arthroscopy are used, along with a distal accessory portal and a posterolateral portal (Fig 1). The gluteal tendon repair may be performed through an iliotibial band window or alternatively may be accessed by direct insertion of the arthroscope into the

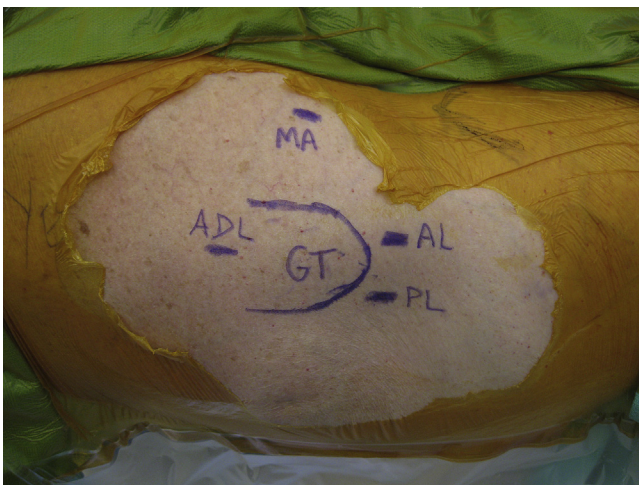


Fig 1. Portals for endoscopic gluteus medius repair. In this lateral view of the left hip with the patient in the supine position, standard hip arthroscopic portals including the anterolateral (AL), posterolateral (PL), and midanterior (MA) portals may be used, in addition to an accessory distal portal (ADL). The greater trochanter (GT) is marked as an anatomic point of reference.

peritrochanteric compartment from the midanterior portal. A potential advantage of the creation of the iliotibial band window is decompression of the greater trochanter and the gluteal insertion. However, the biomechanical effect of the window is unknown, and it is possible that disruption of the iliotibial band may have a deleterious effect on the abductor function of the gluteus maximus and tensor fascia lata.

Creation of Iliotibial Window (Optional)

A Cobb elevator is used to create the plane between the iliotibial band and the overlying fat. The use of a 70° arthroscope allows for improved visualization, because the camera itself functions secondarily as a retractor of the superficial soft tissues. An arthroscopic shaver and an angled ablator with suction are used to remove the overlying soft tissues, creating full visualization of the iliotibial band in its anterior-to-posterior dimension at the level of the greater trochanter. Fluoroscopy may be used to center the window by identifying the proximal and distal extent of the greater trochanter. A cruciform pattern in the iliotibial band is made with a banana blade, creating an approximately 5 × 5-cm window and leaving, at a minimum, a 2-cm anterior and 3-cm posterior band. A cross is made with the banana blade, and the 4 flaps of remaining tissue are resected with a shaver to create a diamond-shaped window (Fig 2). The trochanteric bursae are resected with the shaver and ablator, allowing for visualization of the gluteus medius and minimus insertions and treatment of bursitis.

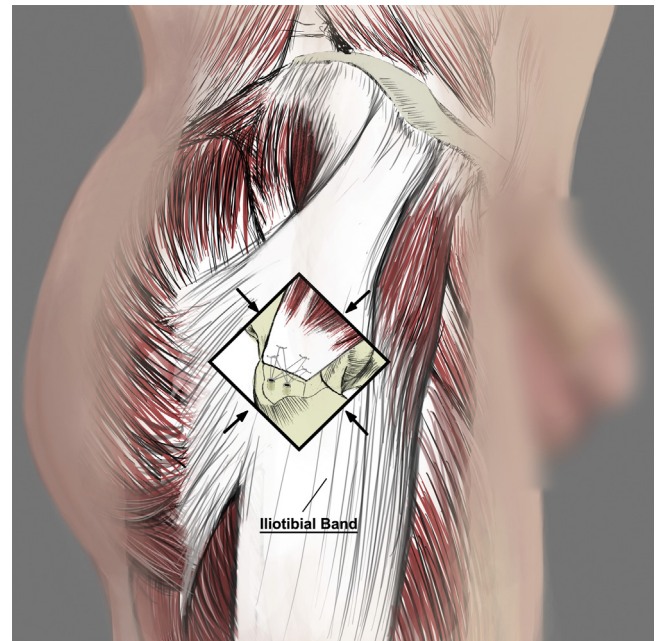


Fig 2. Lateral view of approach to gluteus repair of a right hip. The window in the iliotibial band (arrows) shows the underlying repair with a remaining cuff of iliotibial band both anteriorly and posteriorly. The reinsertion of the gluteal repair centrally along the lateral facet is shown.

Anatomy

An understanding of the anatomy of the insertions of the tendons and of the greater trochanter is important in identifying the injury and in re-creating the gluteal insertion. A detailed review of the arthroscopic and open anatomy of the central and peripheral compartments of the hip has been published.¹³ Furthermore, a computer-generated model of the anatomy of the greater trochanter has delineated the tendon insertions.¹⁴ Figure 3 shows the anatomy of the greater trochanter, with its 4 distinct facets and 3 tendon insertions.¹ The thicker, main component of the gluteus medius inserts at the superoposterior facet. Each of the tendons has a bursa associated with it, which may help to explain somewhat variable results with injections.

The gluteus medius inserts at the greater trochanter at the lateral facet and the superoposterior facet.¹⁴ The gluteus medius originates from the iliac wing and is fan shaped, narrowing to its distal insertion. The muscle has 3 distinct portions—anterior, middle, and posterior—of equal volume. The anterior and middle parts have muscle fibers oriented in a vertical fashion, and they aid in initiating hip abduction.¹⁵ The anterior part is also

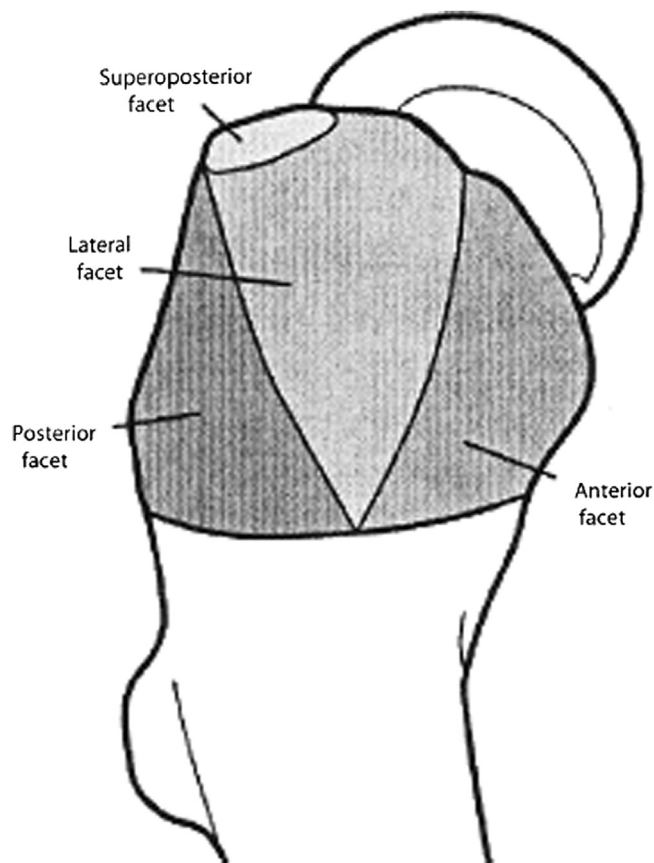


Fig 3. Facets of greater trochanter (lateral view of a right hip). The facets of the greater trochanter show the anatomic position for the gluteus medius insertion at the superoposterior and lateral facets, as well as for the gluteus minimus at the anterior facet.

a primary pelvic rotator. The posterior part of the gluteus medius is oriented horizontally, and it stabilizes the pelvis from heel strike through full stance. The gluteus minimus also has horizontally oriented fibers that stabilize the joint during the mid to late stages of the gait cycle. The gluteus minimus inserts both into the lateral facet (i.e., long head) and into the hip capsule (i.e., capsular head). The capsular attachment on the greater trochanter is located at the anterior facet, and a bald spot is present between this capsular attachment and the lateral facet.

Tendon Reattachment

The gluteal insertion tear is probed and identified. For partial gluteus tendon tears, the option of performing a side-to-side repair may be considered.¹⁴ The degenerated tendon fibers are resected with a shaver before repair, with care to preserve as much healthy tendon as possible. A curved shaver may be used to better access the deep fibers.

The footprint of the torn tendon, on the lateral facet and/or superoposterior facet, is decorticated with a burr to create a bleeding bony bed for healing of the tendon repair. A clear hooded burr, such as the Arthrex ClearCut 4.0 (Arthrex, Naples, FL), is useful in decorticating the bone and protecting the tendon tissue. Large arthroscopic cannulas, such as Smith & Nephew 8.5-mm ClearTrac cannulas (Smith & Nephew, London, England), are useful for suture anchor placement and management. The series of steps involved in gluteal reattachment are shown in Fig 4.

The footprint is re-created with two 4.5-mm BioComposite Corkscrew anchors (Arthrex) with double-loaded No. 2 sutures in the proximal row and two 4.75-mm BioComposite SwiveLock anchors in the distal row (Arthrex). For the 4.5-mm BioComposite Corkscrew anchors, a 4.5-mm punch and a 4.5-mm tap may be used for placement. For the 4.75-mm BioComposite SwiveLock anchors, a 4.5-mm or 5.5-mm punch may be used depending on bone density, as well as a 4.75-mm tap. The proximal row allows knot-tying fixation. The distal-row fixation creates a weave of suture material, creating a large area of tendon apposition to bone. The angle of passage of the anchors into the decorticated bone is 45°. The proximal-row anchors are placed first, with care to pass the sutures through the tendon tissue with appropriate spacing across the width of the gluteal tendon. Overlap in the sagittal plane is performed with the adjacent suture passed slightly proximally or distally in the tendon.

Once all 8 limbs have been passed, the sutures can be tied with a standard knot-tying technique from the posterolateral portal while one is visualizing from the distal accessory portal. The second or distal row is then secured by passing 1 limb from each tied suture into each of the 2 distal SwiveLock anchors. This passage

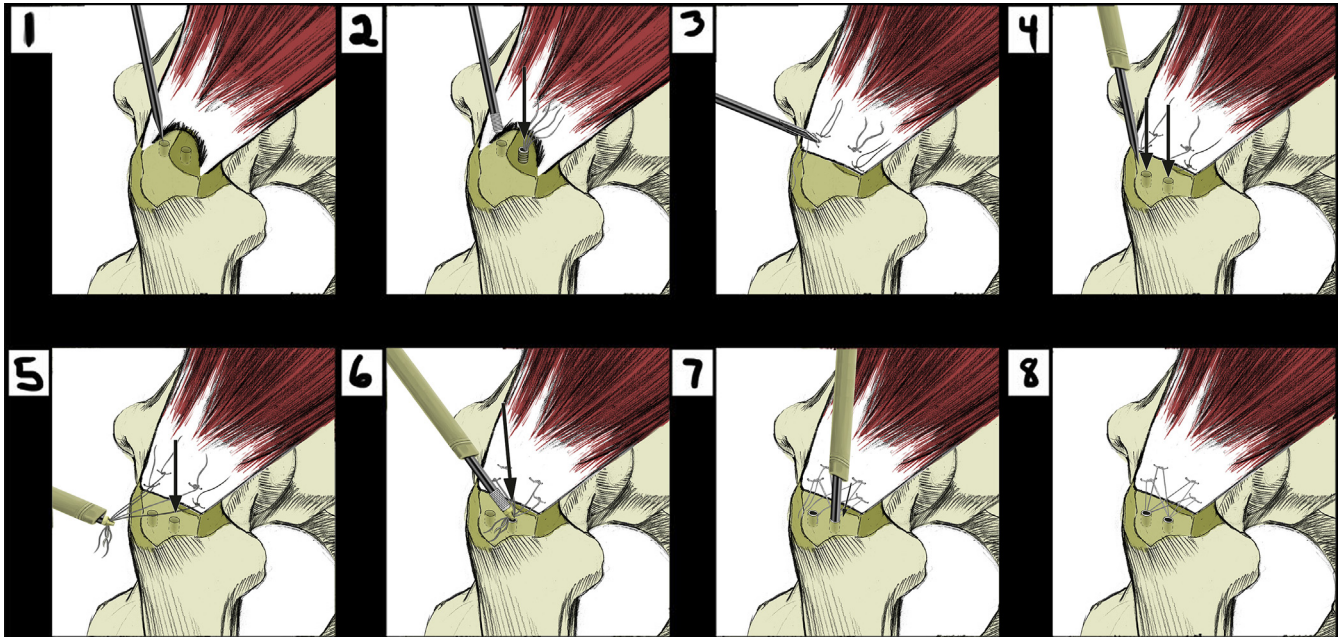


Fig 4. Lateral view of a right hip showing the steps in re-creating the footprint for gluteal insertional repair. (1) Pilot holes are made in the proximal row for anchor placement. (2) Two double-loaded anchors are placed in the proximal row. The arrow shows the anterior anchor placement of the 2 anchors placed in the proximal row. (3) Eight limbs of suture are passed through the gluteus tendon with equal spacing across the tendon, and the sutures are tied. (4) Arrows show the holes that have been punched for distal-row fixation. (5) Four limbs are passed through the anterior SwiveLock of the distal row, created by passing one limb from each knot that was tied in the proximal row. The tension is set in the sutures before insertion of the anchor. The arrow shows the hole into which the SwiveLock is placed. (6) The tension on the sutures of the anterior SwiveLock anchor is adjusted before seating of the SwiveLock (arrow). (7) Insertion of distal-row SwiveLock anchor. (8) Final construct.

of suture into the SwiveLock anchor creates a crossed pattern of suture material with knotless fixation distally. For the SwiveLock anchors, the tension of the sutures is set before seating them with a mallet.

Alternatively, a 4-limb suture technique can be used for gluteal repair fixation, with 2 limbs passed into each distal row for fixation. The clinical outcomes when comparing an 8- versus 4-limb technique have not been shown.

In a biomechanical comparison of repair techniques for the gluteal insertion, the technique shown in our study, named the double-row repair with knotless lateral anchors, showed similar stability to an alternative repair technique, the double-row repair with massive cuff stitches.¹⁶ However, the maximum load was strongly correlated to bone mineral density in the group undergoing double-row repair with knotless lateral anchors. The ideal construct for patients with low bone mineral density.

Outcomes

No large or randomized clinical studies have been performed to date to evaluate the efficacy of the described endoscopic technique, including a comparison to open repair. The advantages noted in other anatomic areas when comparing endoscopic versus open repair have included lower risk of infection, decreased postoperative pain, and accelerated rehabilitation. Potential limitations

of the endoscopic technique include the inability to mobilize large chronic gluteal tears and the technical difficulty and learning curve inherent to endoscopic techniques, including maintenance of visualization, suture passage and management, and maintenance of hemostasis when resecting the highly vascularized bursitis. Complications include tendon re-tear, over-resection of the iliotibial band resulting in herniation of muscle or external snapping, and recurrence of bursitis. Conversion to an open technique may be necessary.

Postoperative Rehabilitation

Patients are placed in an X-Act range-of-motion low-profile abduction hip brace (DJO Global, Vista, CA) (Fig 5) and are touchdown weight bearing for 6 weeks after surgery. Physical therapy is initiated within 2 to 3 days after surgery. Gentle passive stretching in abduction is started at 2 weeks and otherwise full range of motion is permitted immediately postoperatively. At 6 weeks postoperatively, weight bearing is permitted as tolerated, and ambulating distances are gradually increased over a period of 4 weeks. The hip brace is discontinued at 8 weeks. Strengthening is initiated at 12 weeks postoperatively.

Conclusions

Gluteal insertion tendon tears are often a misdiagnosed cause of chronic debilitating lateral hip pain. We present

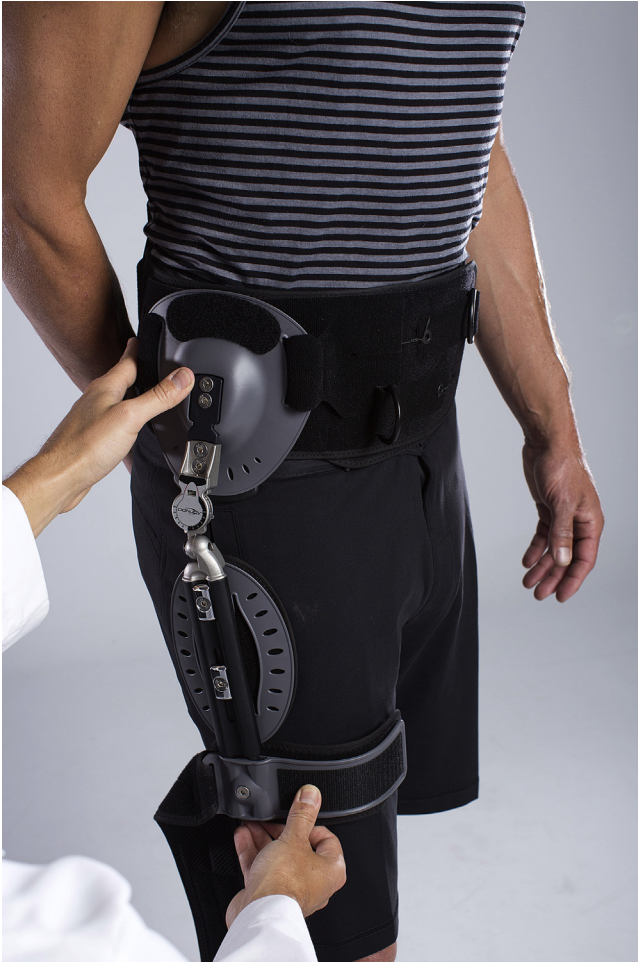

Fig 5. DJO Global hip brace used postoperatively to protect gluteal insertional repair.

an endoscopic double-row technique for gluteal insertional repair that allows for visualization, debridement, and repair, re-creating the normal footprint. Increasing recognition of the gluteal insertion as a cause of chronic pain and weakness, as well as technologic advances in endoscopic hip surgery, have made gluteal insertional repair a rapidly emerging technique in minimally invasive surgery of the hip.

References

1. Domb BG, Nasser RM, Botser IB. Partial-thickness tears of the gluteus medius: Rationale and technique for

trans-tendinous endoscopic repair. *Arthroscopy* 2010;26:1697-1705.

2. Karpinski MR, Piggott H. Greater trochanteric pain syndrome. A report of 15 cases. *J Bone Joint Surg Br* 1985;67:762-763.
3. Dwek J, Pfirrmann C, Stanley A, Pathria M, Chung CB. MR imaging of the hip abductors: Normal anatomy and commonly encountered pathology at the greater trochanter. *Magn Reson Imaging Clin N Am* 2005;13:691-704, vii.
4. Connell DA, Bass C, Sykes CA, Young D, Edwards E. Sonographic evaluation of gluteus medius and minimus tendinopathy. *Eur Radiol* 2003;13:1339-1347.
5. Kingzett-Taylor A, Tirman PF, Feller J, et al. Tendinosis and tears of gluteus medius and minimus muscles as a cause of hip pain: MR imaging findings. *AJR Am J Roentgenol* 1999;173:1123-1126.
6. Bunker TD, Esler CN, Leach WJ. Rotator-cuff tear of the hip. *J Bone Joint Surg Br* 1997;79:618-620.
7. El-Husseiny M, Rayan F, Haddad F. Gluteus medius tears: An under-diagnosed pathology. *Br J Hosp Med* 2011;72:12-16.
8. Davies H, Zhaentan S, Tavakkolizadeh A, Janes G. Surgical repair of chronic tears of the hip abductor mechanism. *Hip Int* 2009;19:372-376.
9. Cormier G, Maugars Y. Gluteus tendon rupture is underrecognized by French orthopedic surgeons: Results of a small survey. *Joint Bone Spine* 2006;73:411-413.
10. Voos JE, Rudzki JR, Shindle MK, Martin H, Kelly BT. Arthroscopic anatomy and surgical techniques for peritrochanteric space disorders in the hip. *Arthroscopy* 2007;23:1246.e1-1246.e5.
11. Voos JE, Shindle MK, Pruett A, Asnis PD, Kelly BT. Endoscopic repair of gluteus medius tendon tears of the hip. *Am J Sports Med* 2009;37:743-747.
12. Blankenbaker DG, Ullrick SR, Davis KW, De Smet AA, Haaland B, Fine JP. Correlation of MRI findings with clinical findings of trochanteric pain syndrome. *Skeletal Radiol* 2008;37:903-909.
13. Ranawat AS, Kelly BT. Anatomy of the hip: Open and arthroscopic structure and function. *Oper Tech Orthop* 2005;15:160-174.
14. Robertson WJ, Gardner MJ, Barker JU, Boraiah S, Lorich DG, Kelly BT. Anatomy and dimensions of the gluteus medius tendon insertion. *Arthroscopy* 2008;24:130-136.
15. Gottschalk F, Kourosch S, Leveau B. The functional anatomy of tensor fasciae latae and gluteus medius and minimus. *J Anat* 1989;166:179-189.
16. Dishkin-Paset JG, Salata MJ, Gross CE, et al. A biomechanical comparison of repair techniques for complete gluteus medius tears. *Arthroscopy* 2012;28:1410-1416.